

Case Presentation: A-Branch Endograft after heart transplant

Carlos H. Timaran, MD

Division of Vascular and Endovascular Surgery
UT Southwestern, Dallas, TX, USA

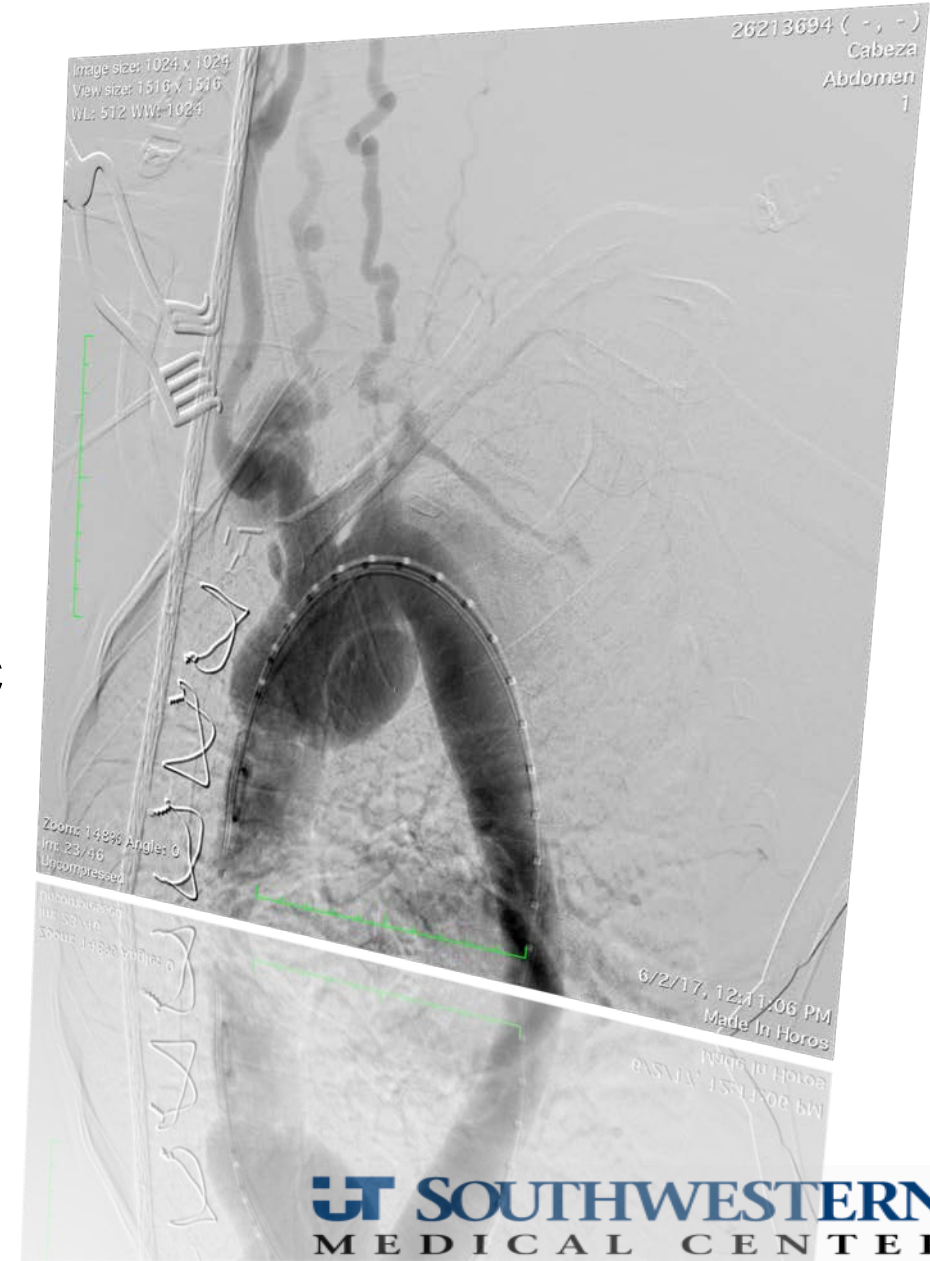
Disclosures

Research support, consulting &
proctoring

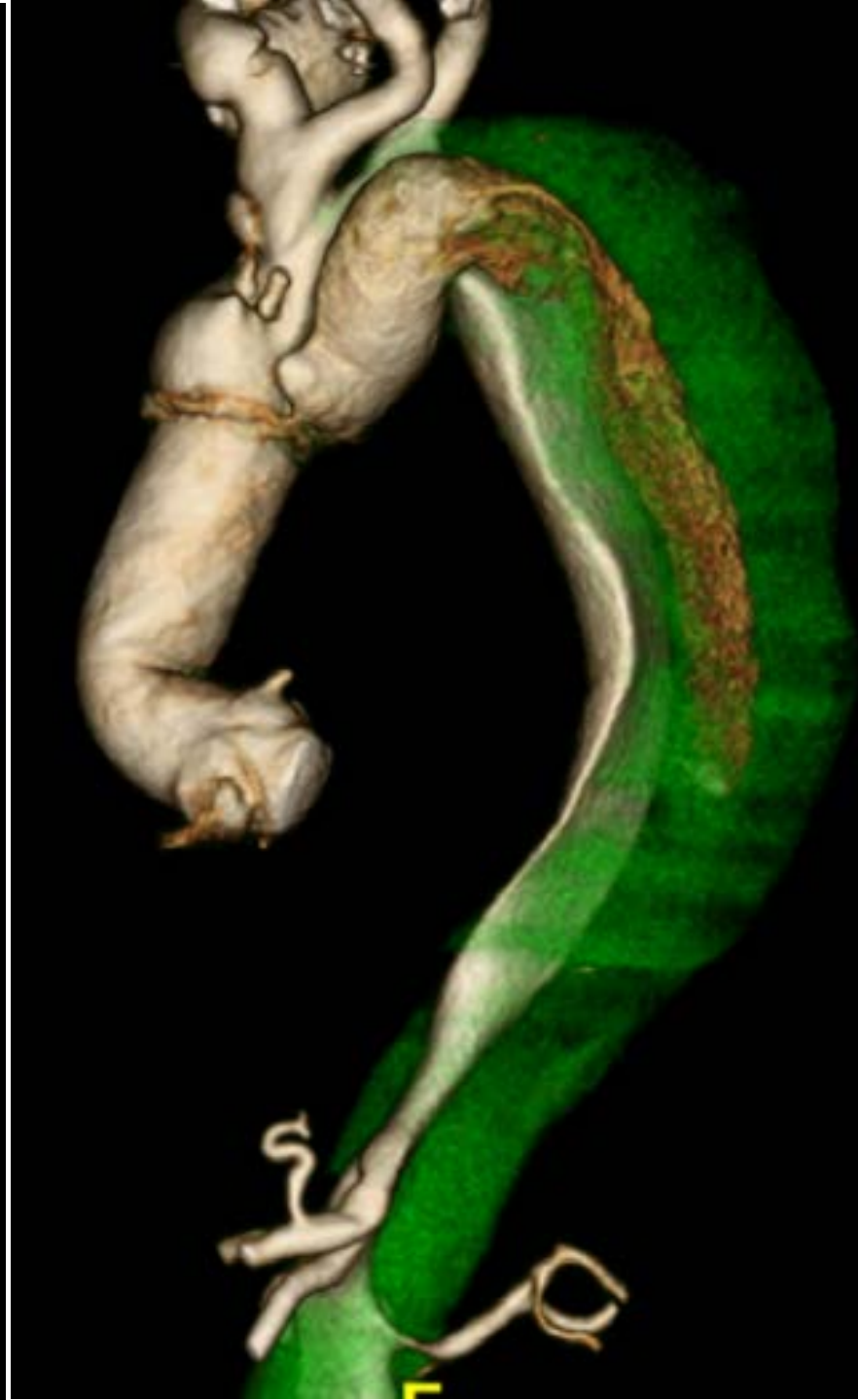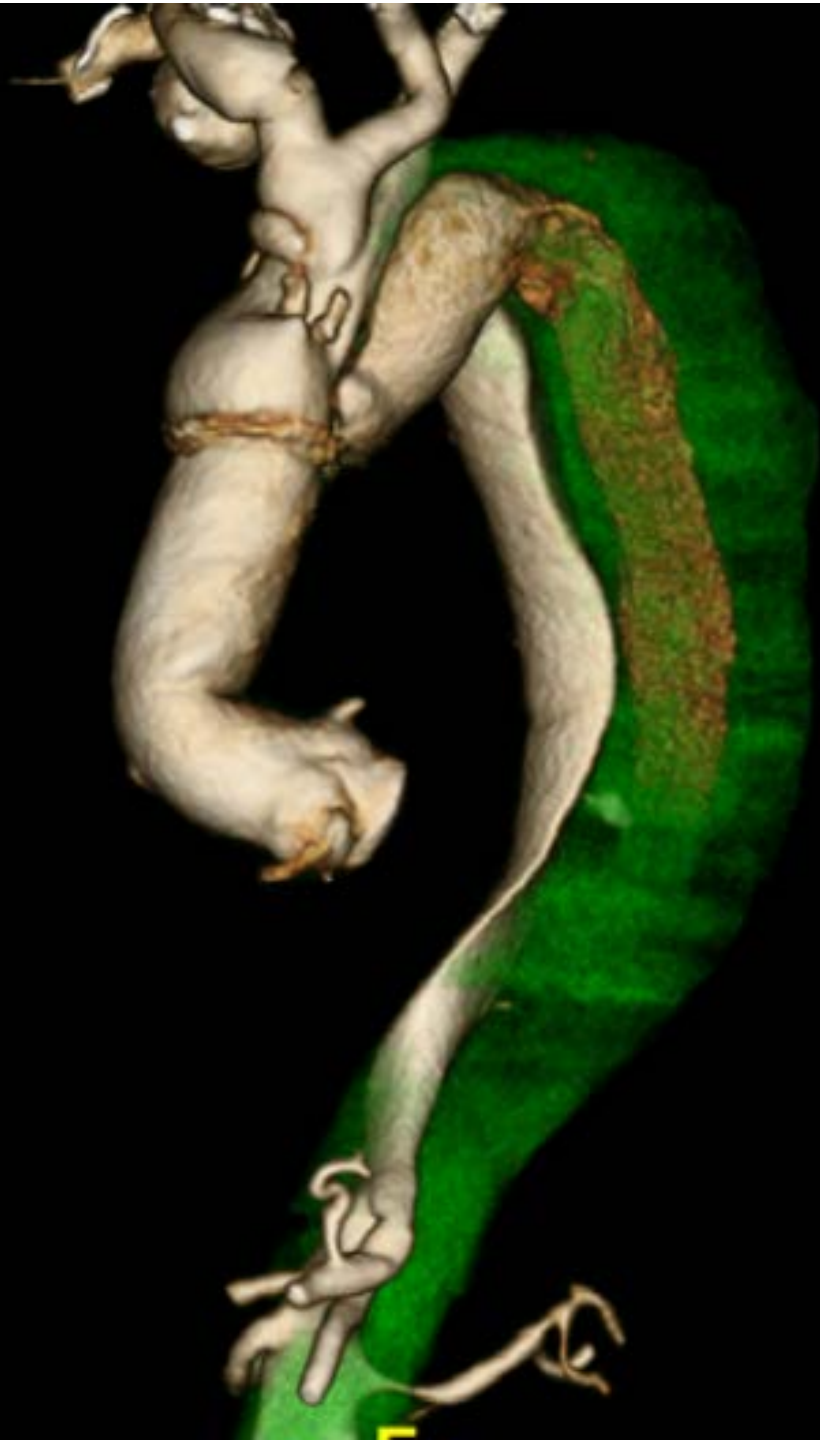- Cook Medical Inc.

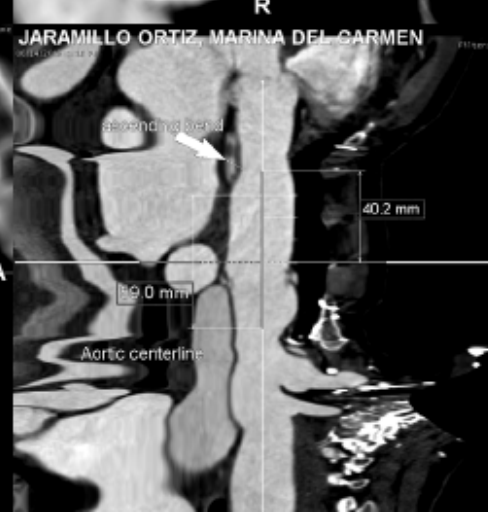
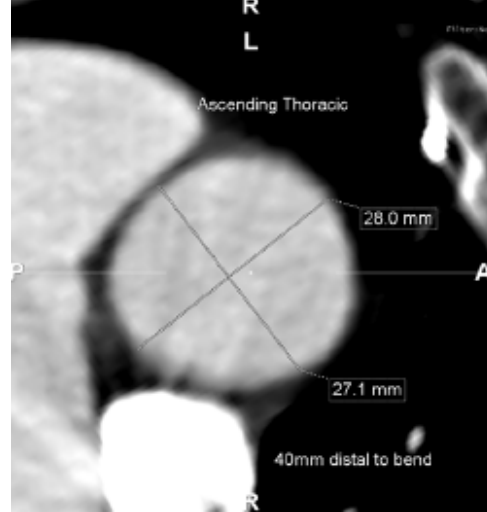
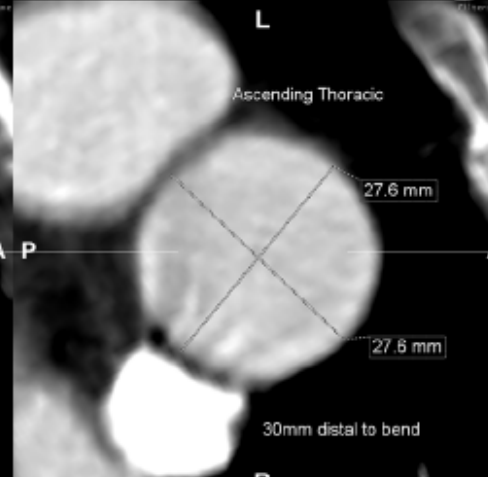
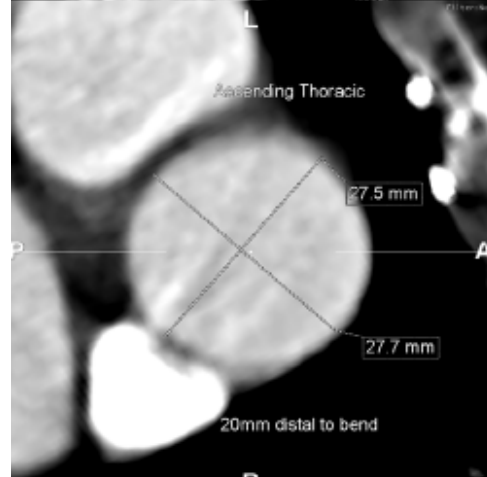
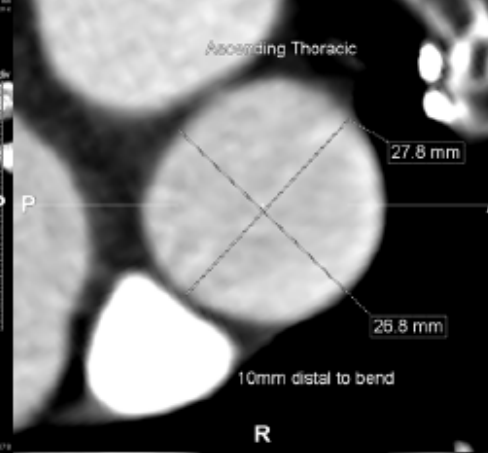
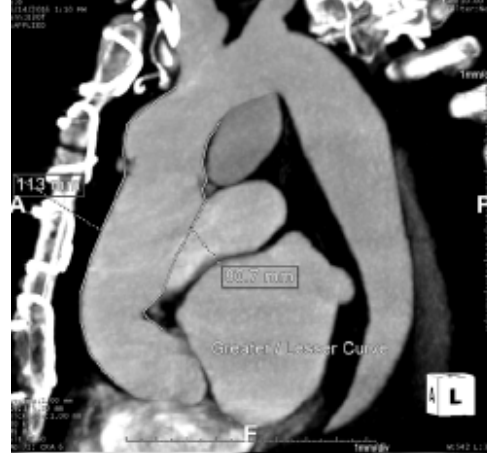Case presentation

- 55-year old female
- Heart transplant 3 years earlier
- On POD 5, patient developed acute aortic dissection type A that required open repair
- Residual arch and descending thoracic aortic dissection
- Progressive aortic enlargement now measuring 6 cm at the level of the arch
- High-risk for open repair









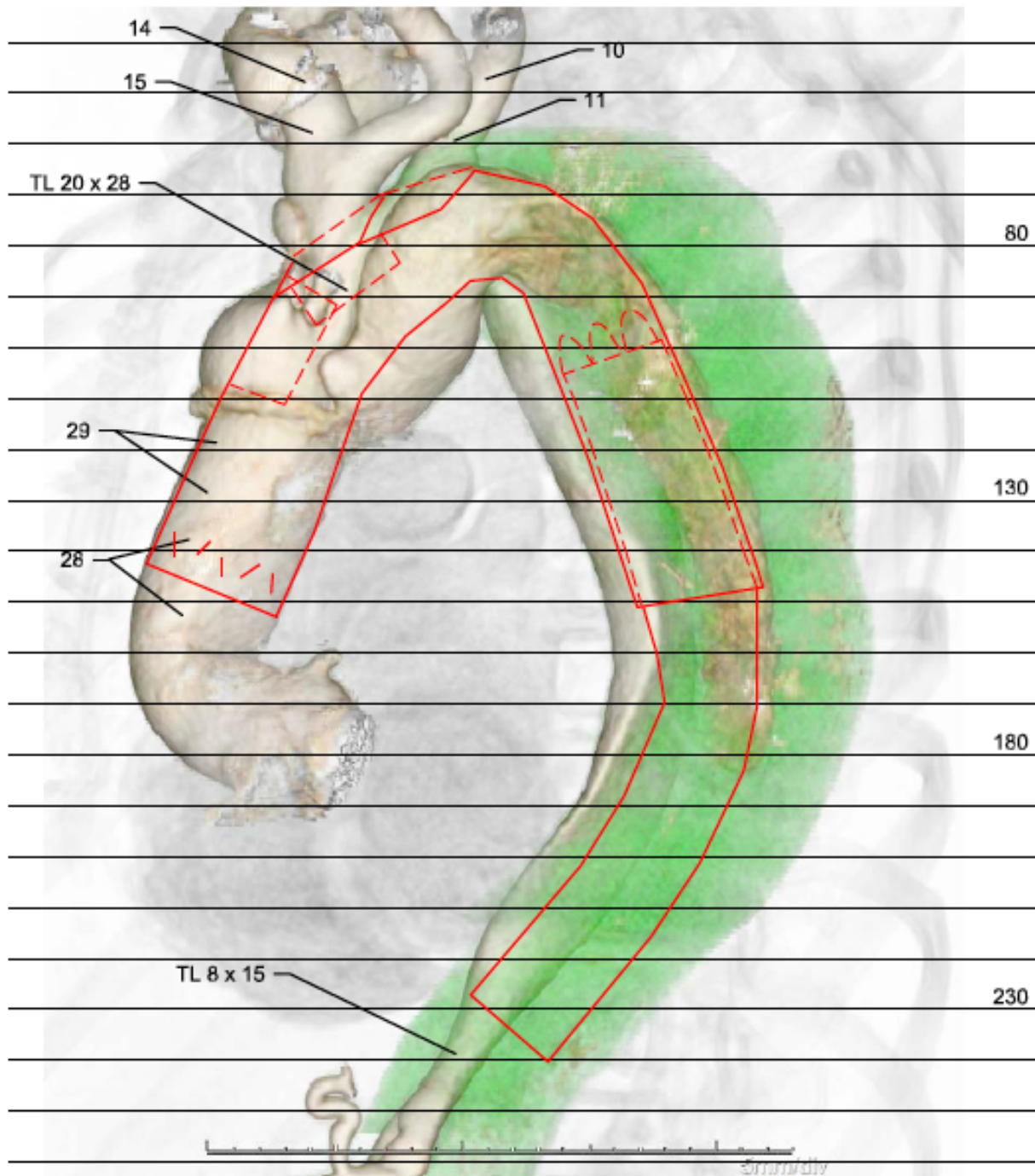


Image size: 1024 x 1024
View size: 1516 x 1516
WL: 512 WW: 1024

26213694 (- , -)
Cabeza
Abdomen
1



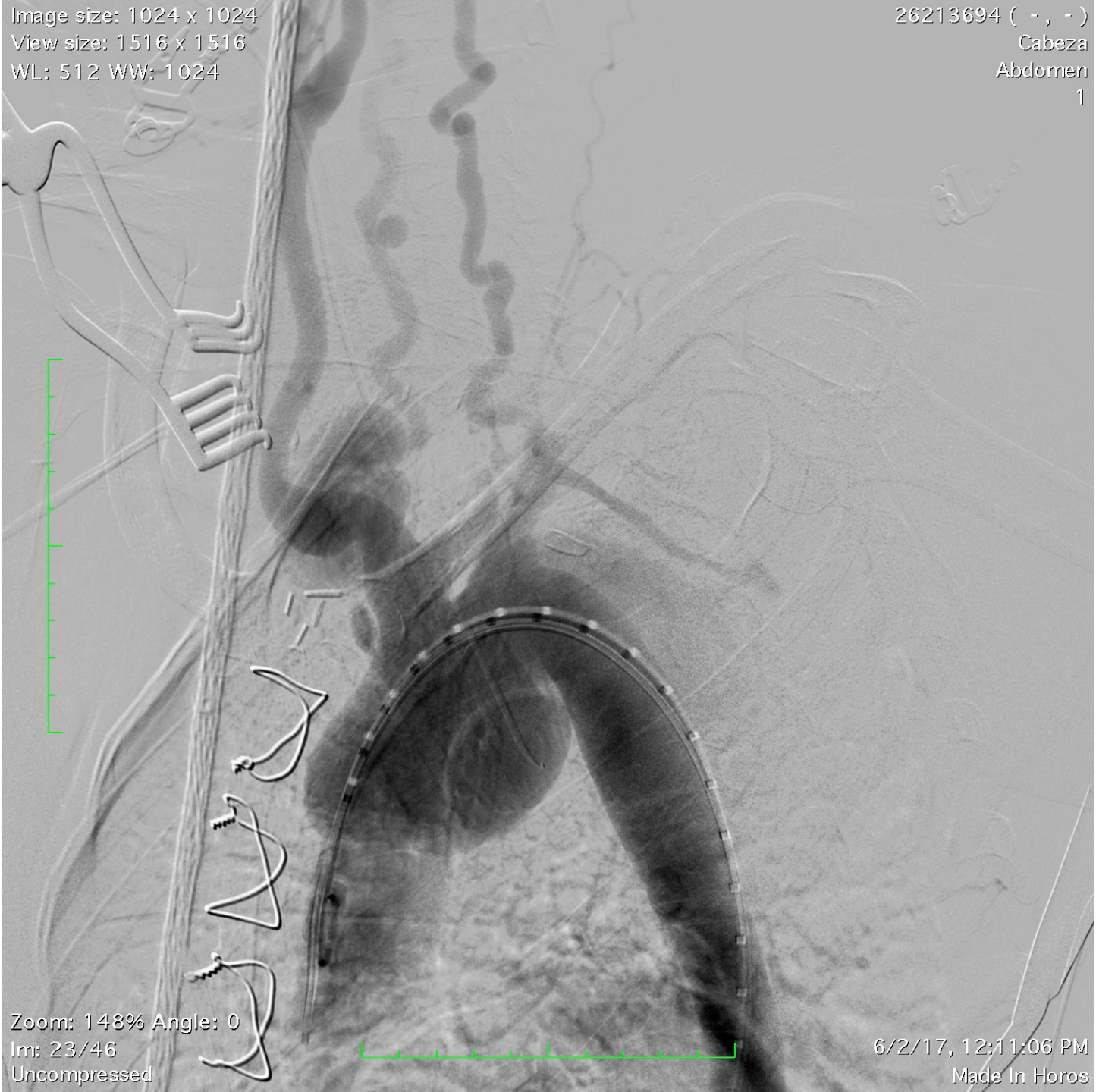Zoom: 148% Angle: 0
Im: 1/46
Uncompressed



6/2/17, 12:11:06 PM
Made In Horos

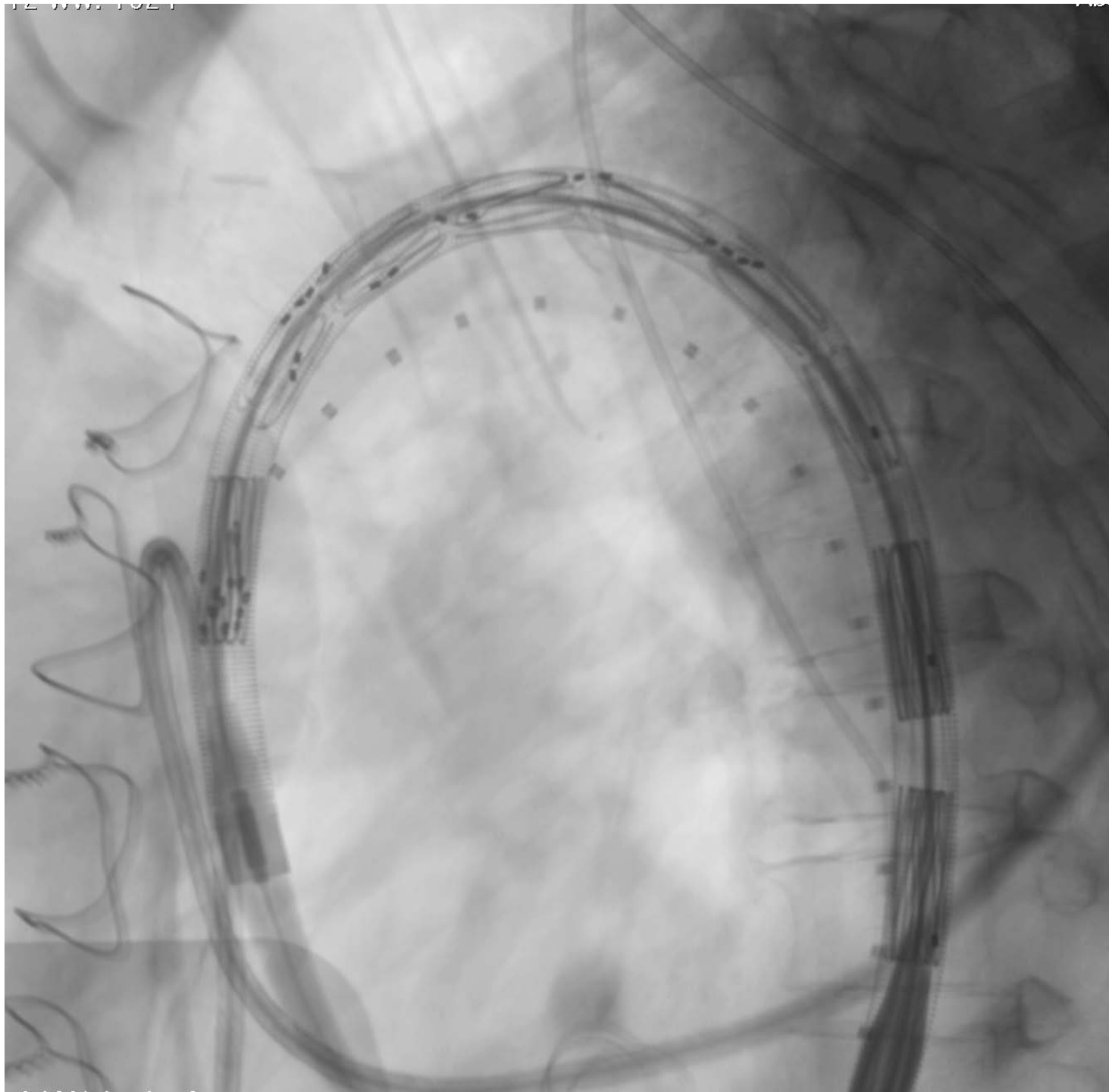
Image size: 1024 x 1024
View size: 1516 x 1516
WL: 512 WW: 1024

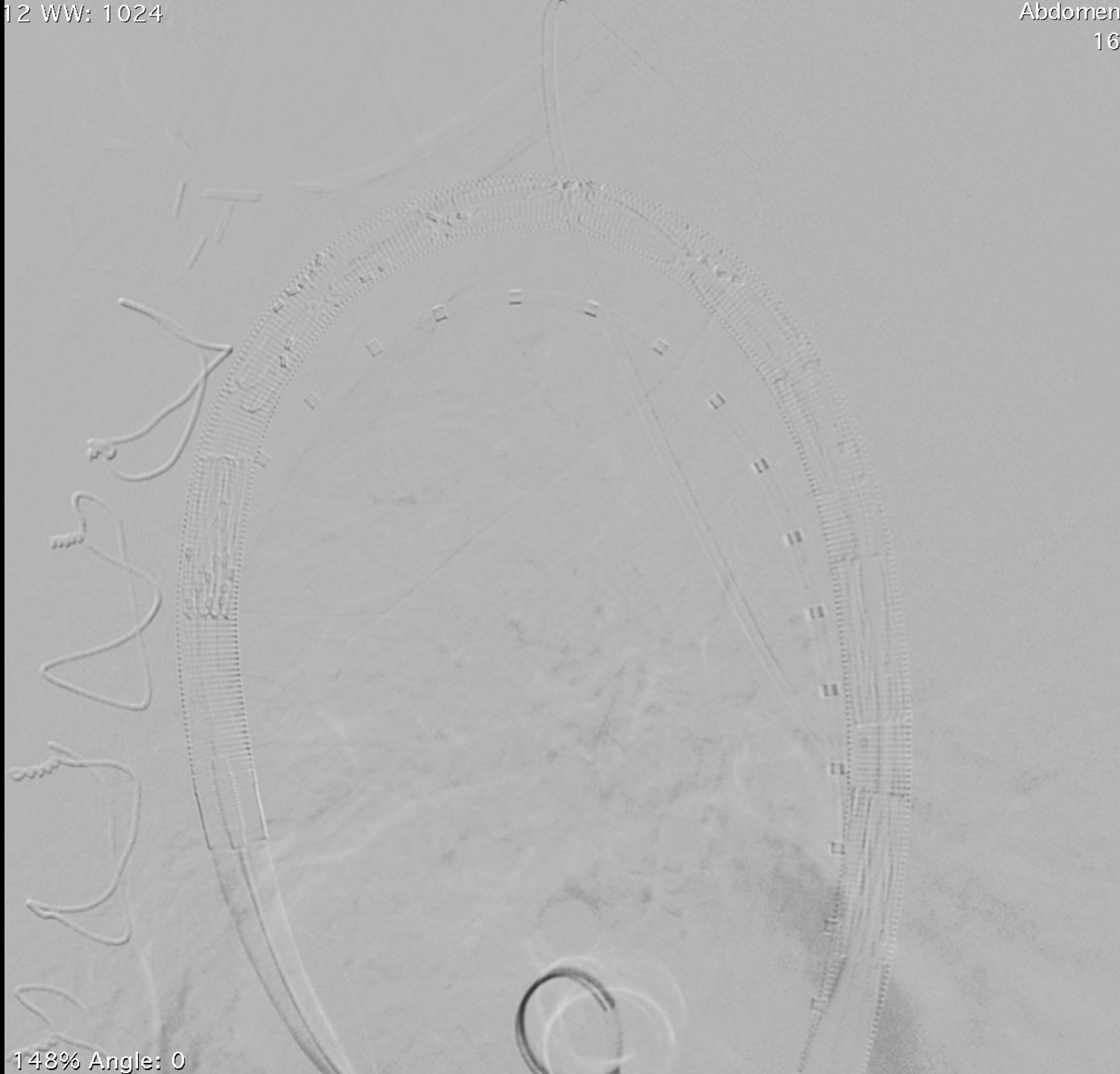26213694 (- , -)
Cabeza
Abdomen
1

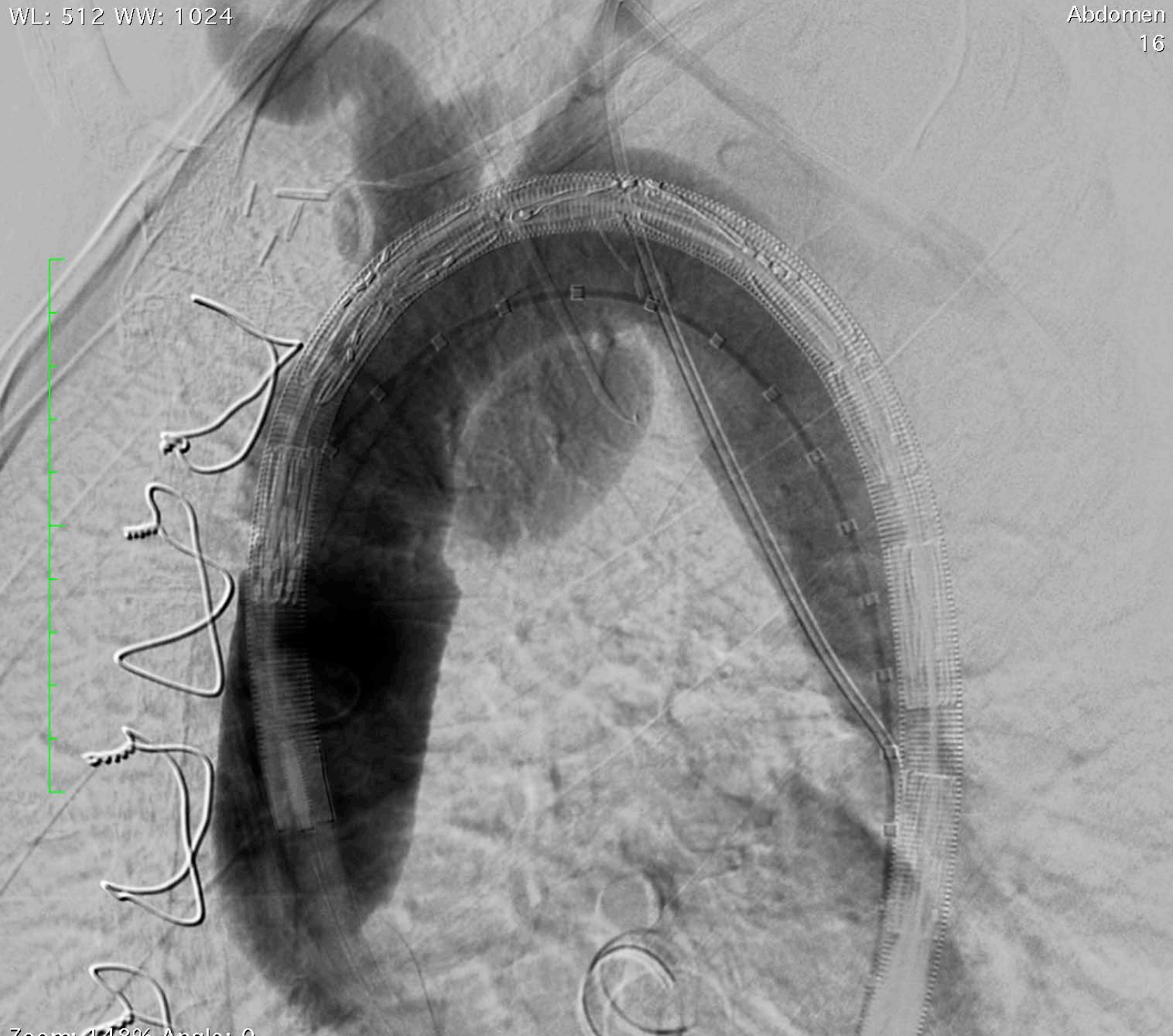

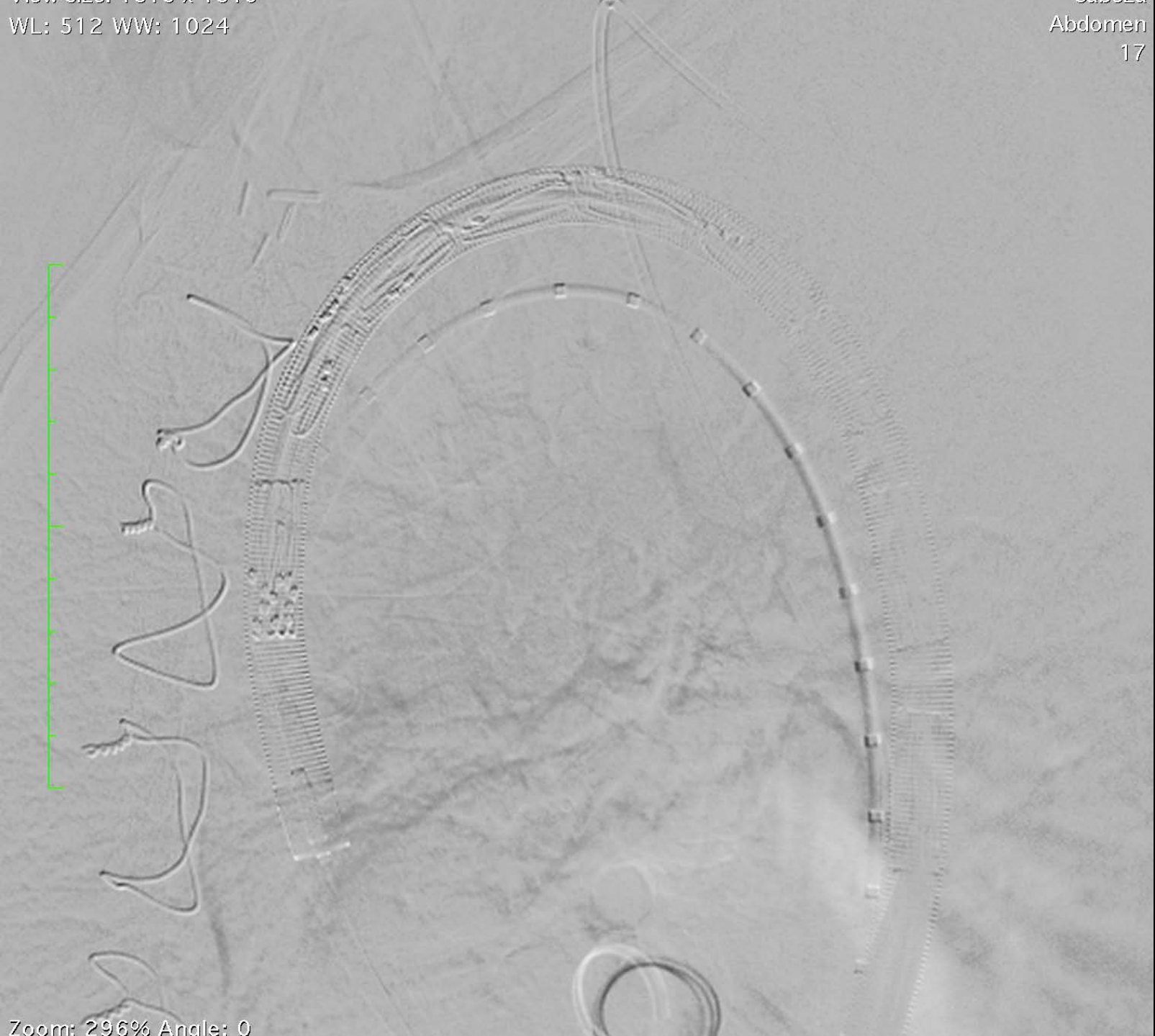Zoom: 148% Angle: 0
Im: 23/46
Uncompressed

6/2/17, 12:11:06 PM
Made In Horos



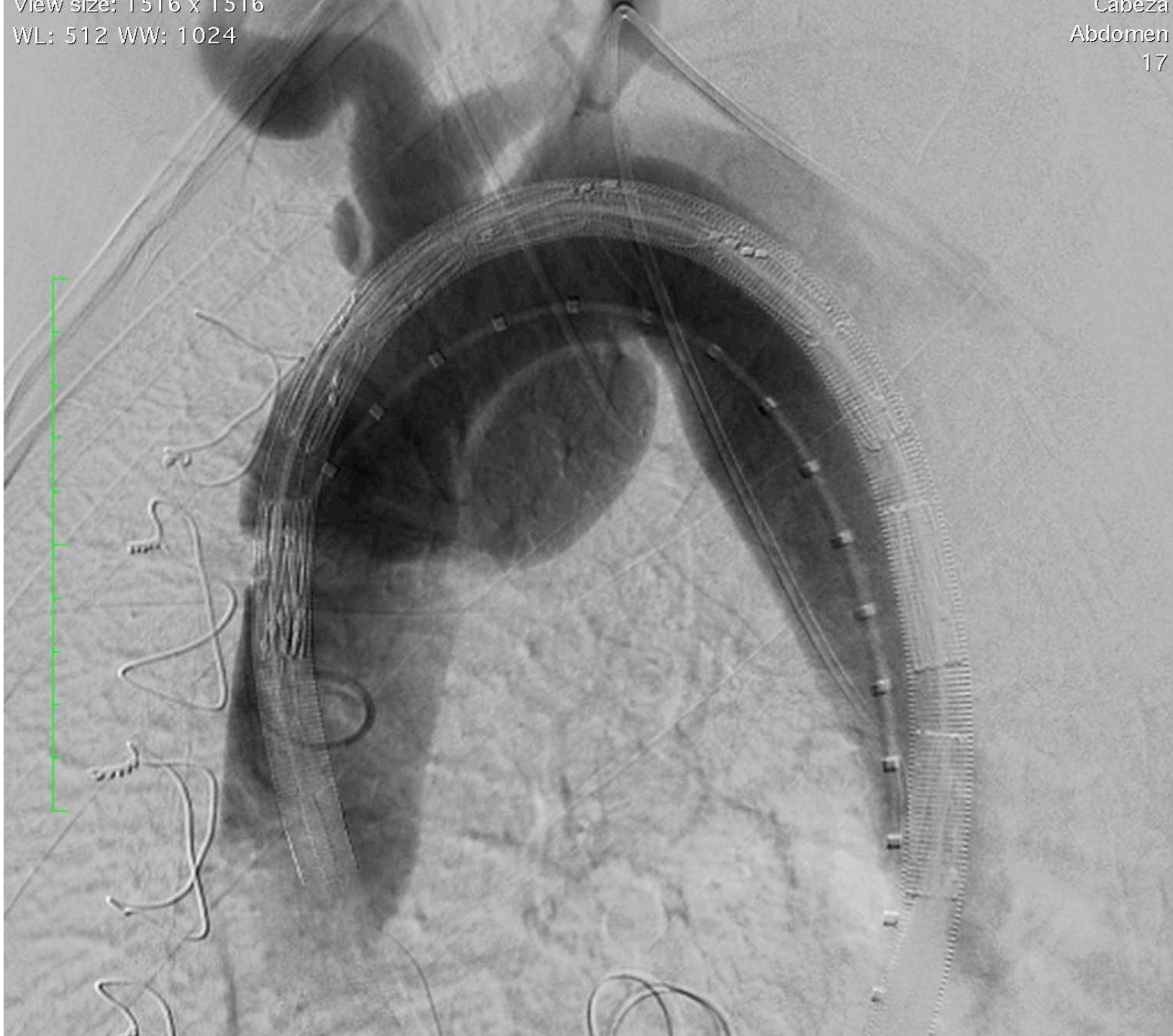


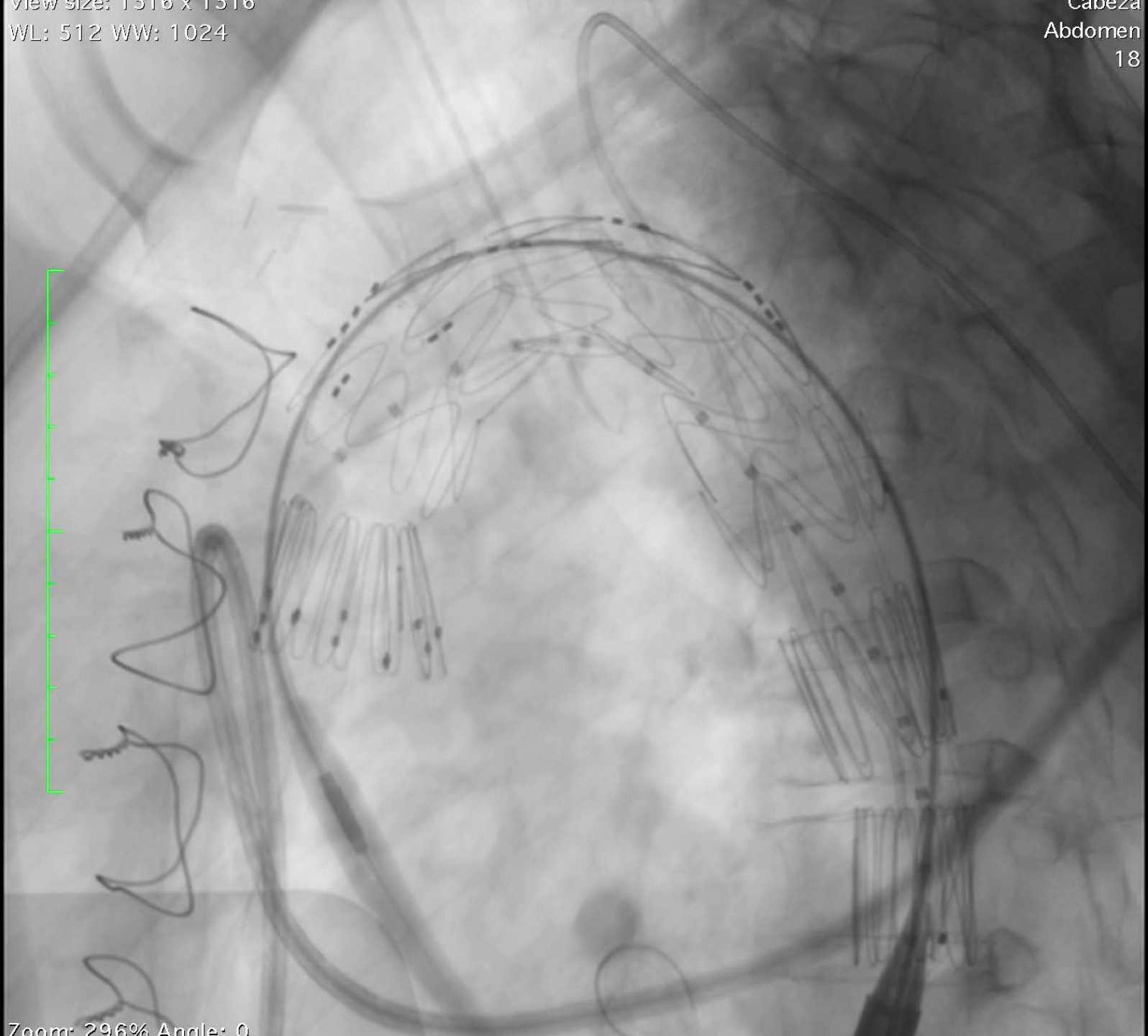


view size: 1516 x 1516
WL: 512 WW: 1024

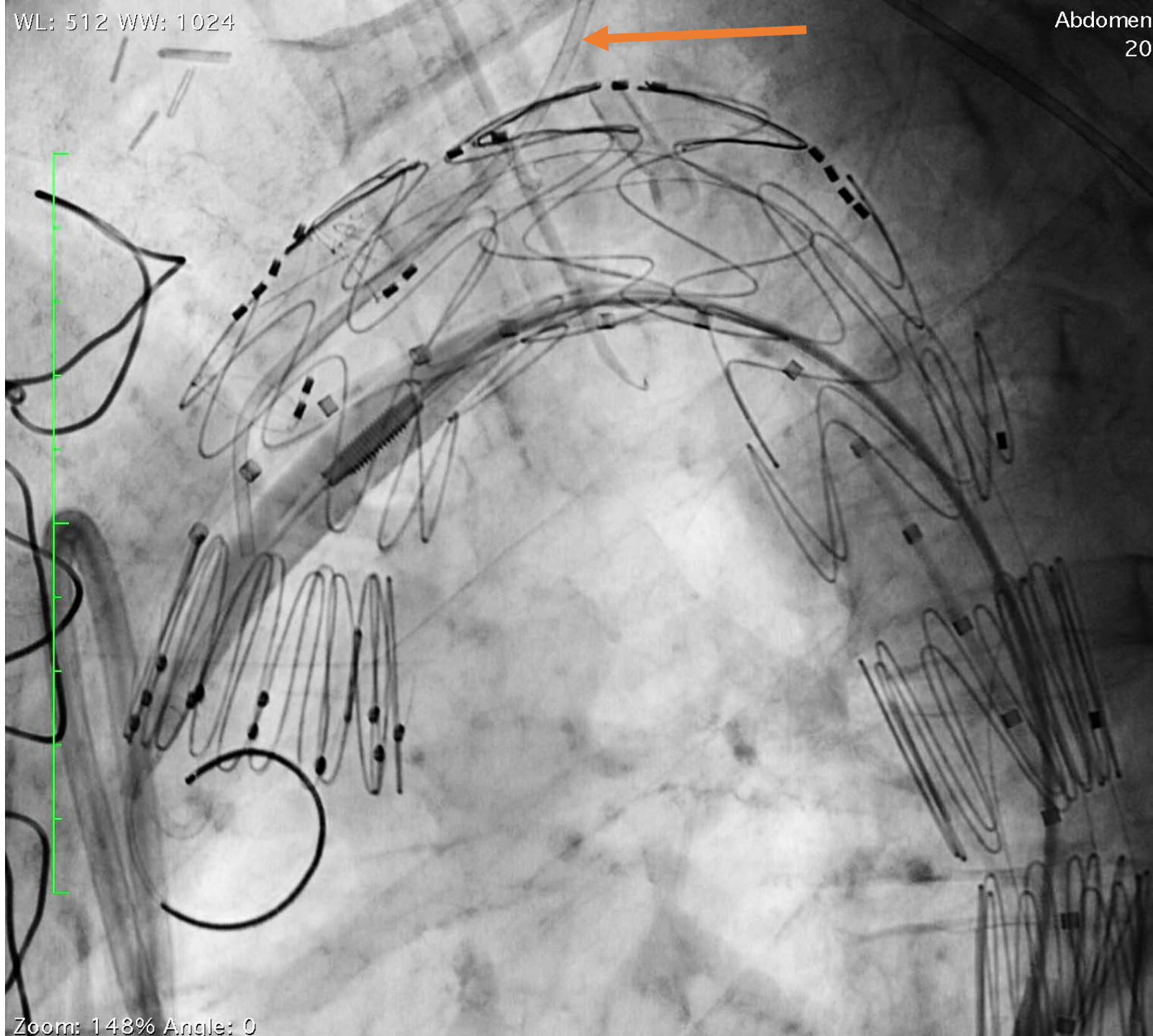Cabeza
Abdomen
17





WL: 512 WW: 1024

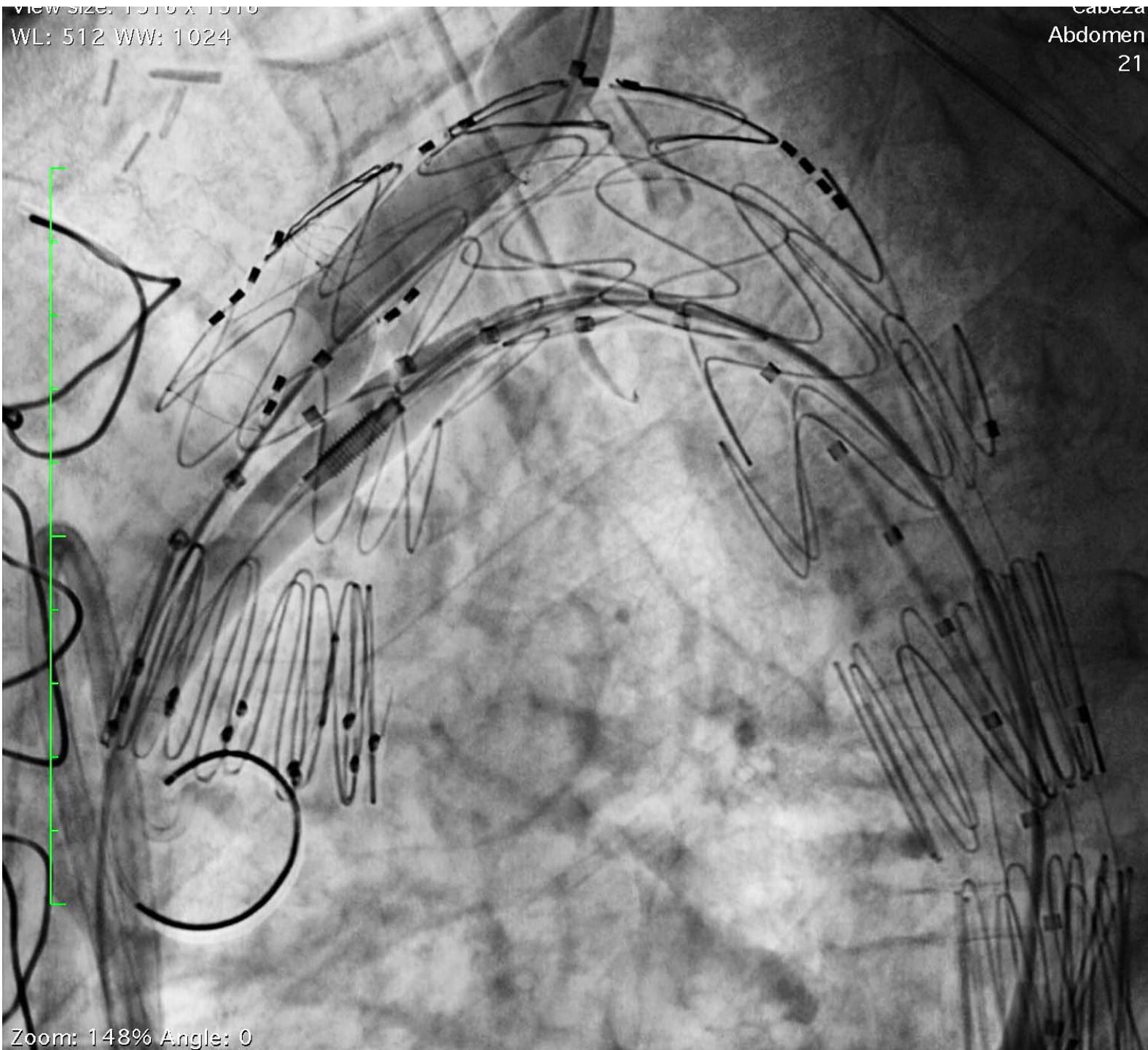
Abdomen
20



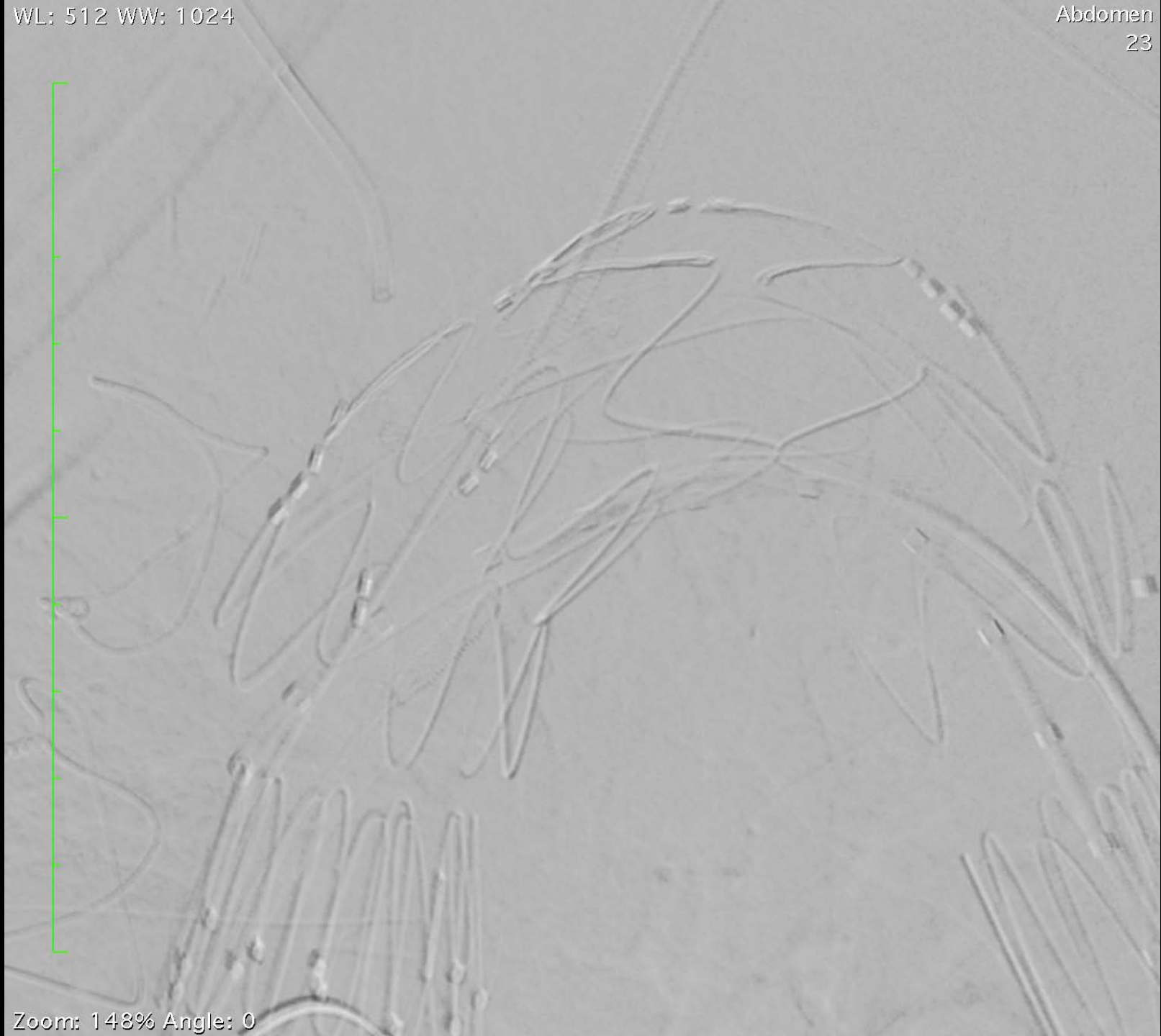Zoom: 148% Angle: 0

view size: 1510 x 1510
WL: 512 WW: 1024

Cabeza
Abdomen
21

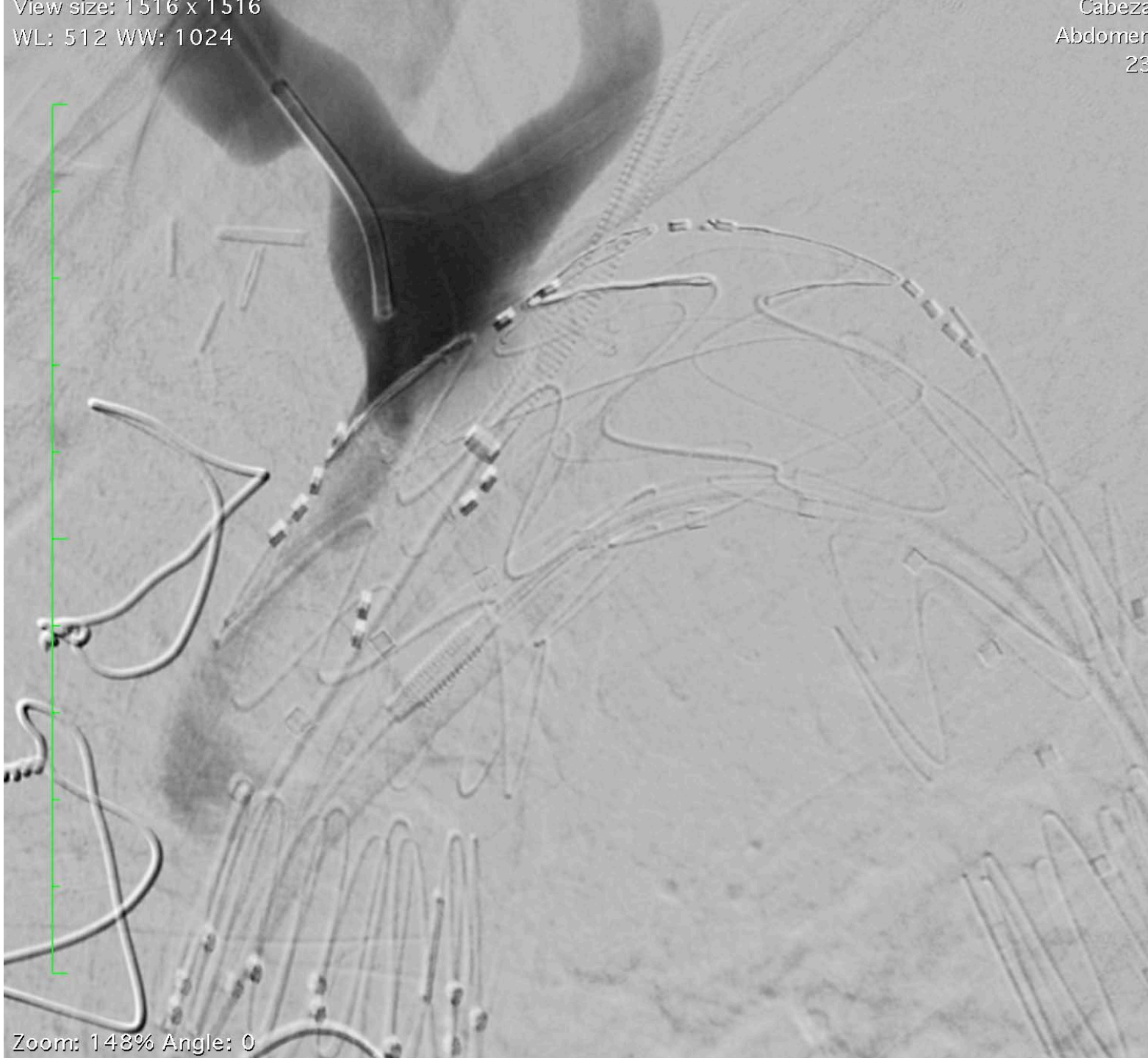

Zoom: 148% Angle: 0



View size: 1516 x 1516
WL: 512 WW: 1024

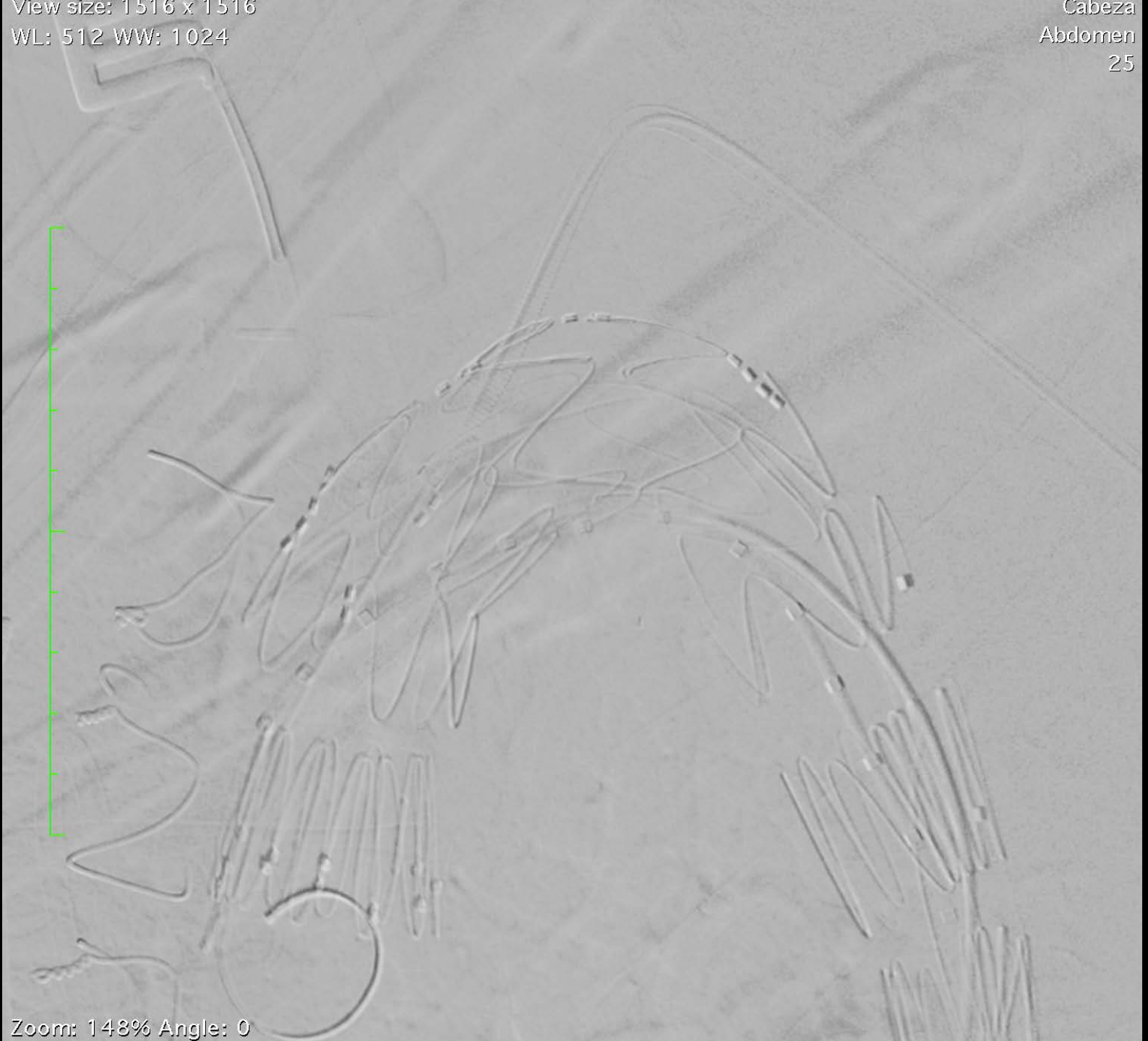Cabeza
Abdomen
23



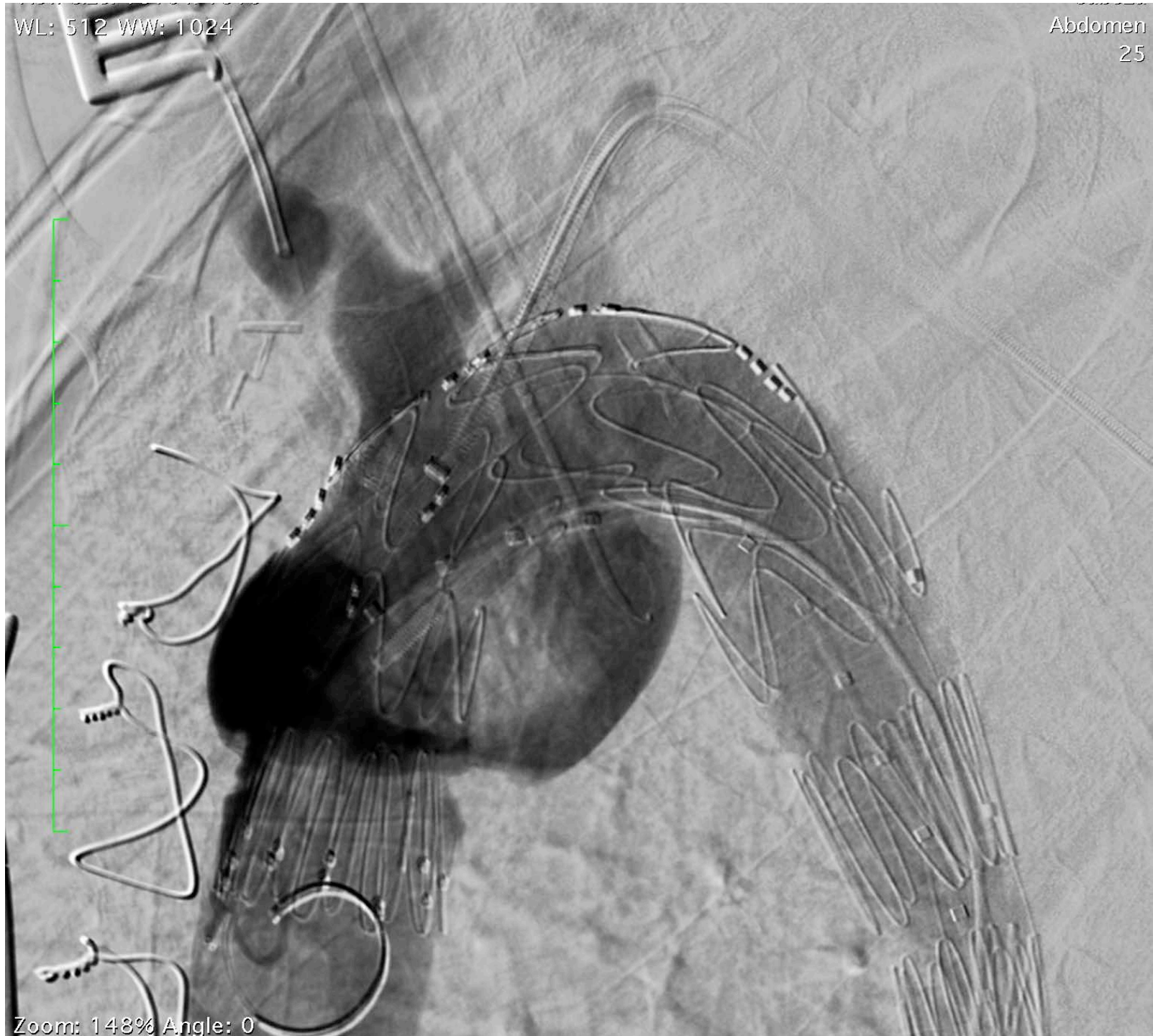
Zoom: 148% Angle: 0

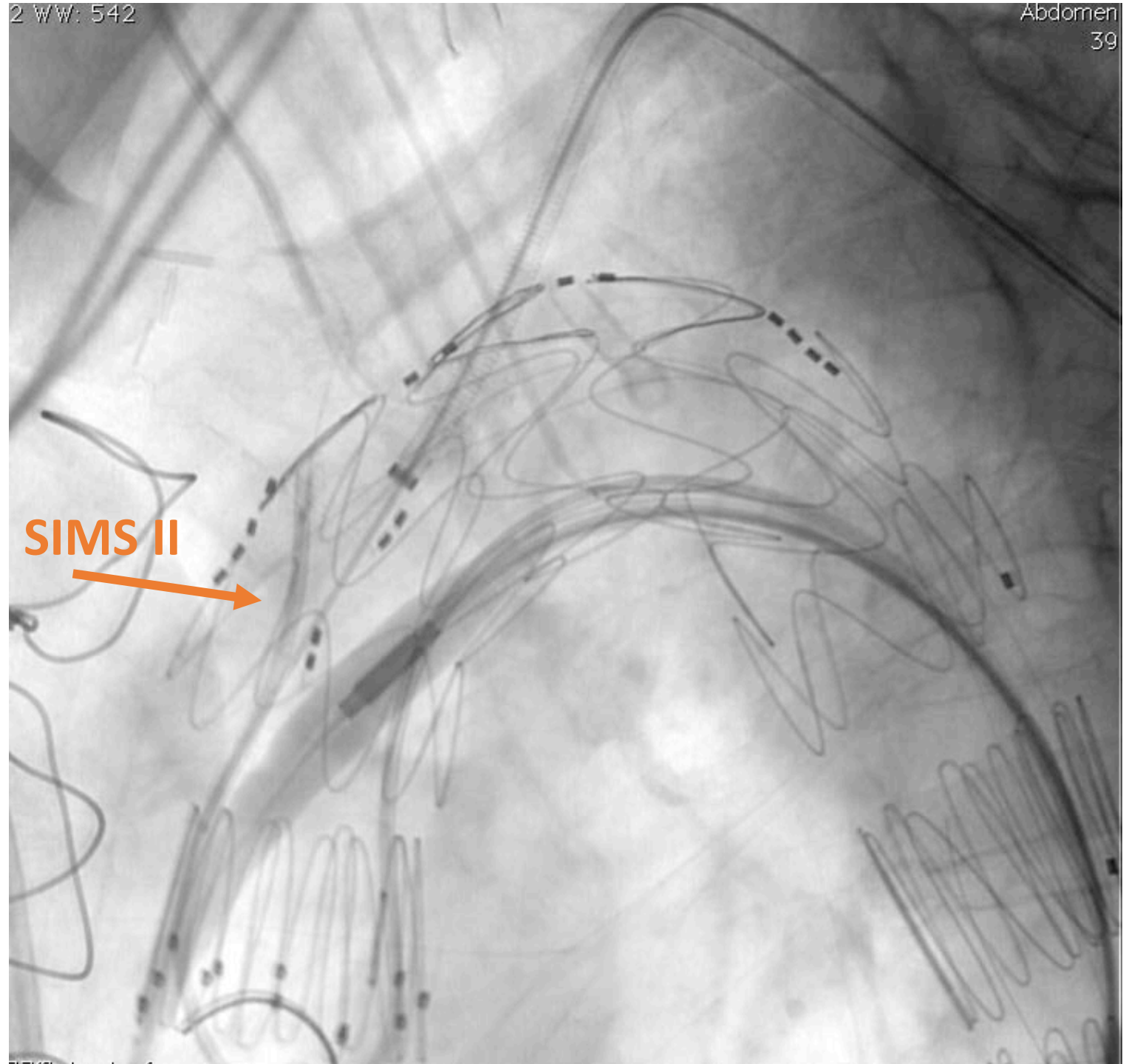
View size: 1516 x 1516
WL: 512 WW: 1024

Cabeza
Abdomen
25



Zoom: 148% Angle: 0

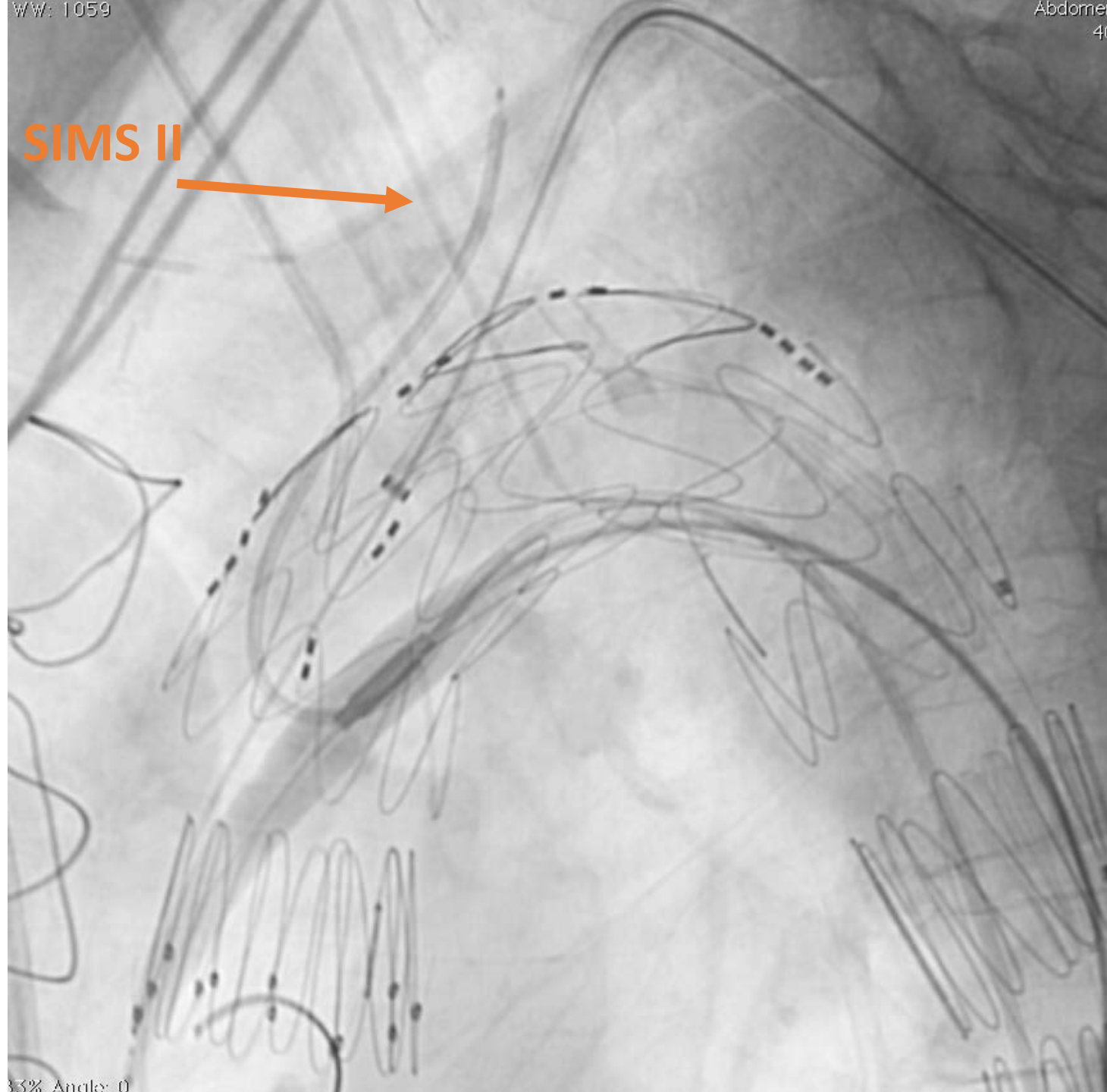




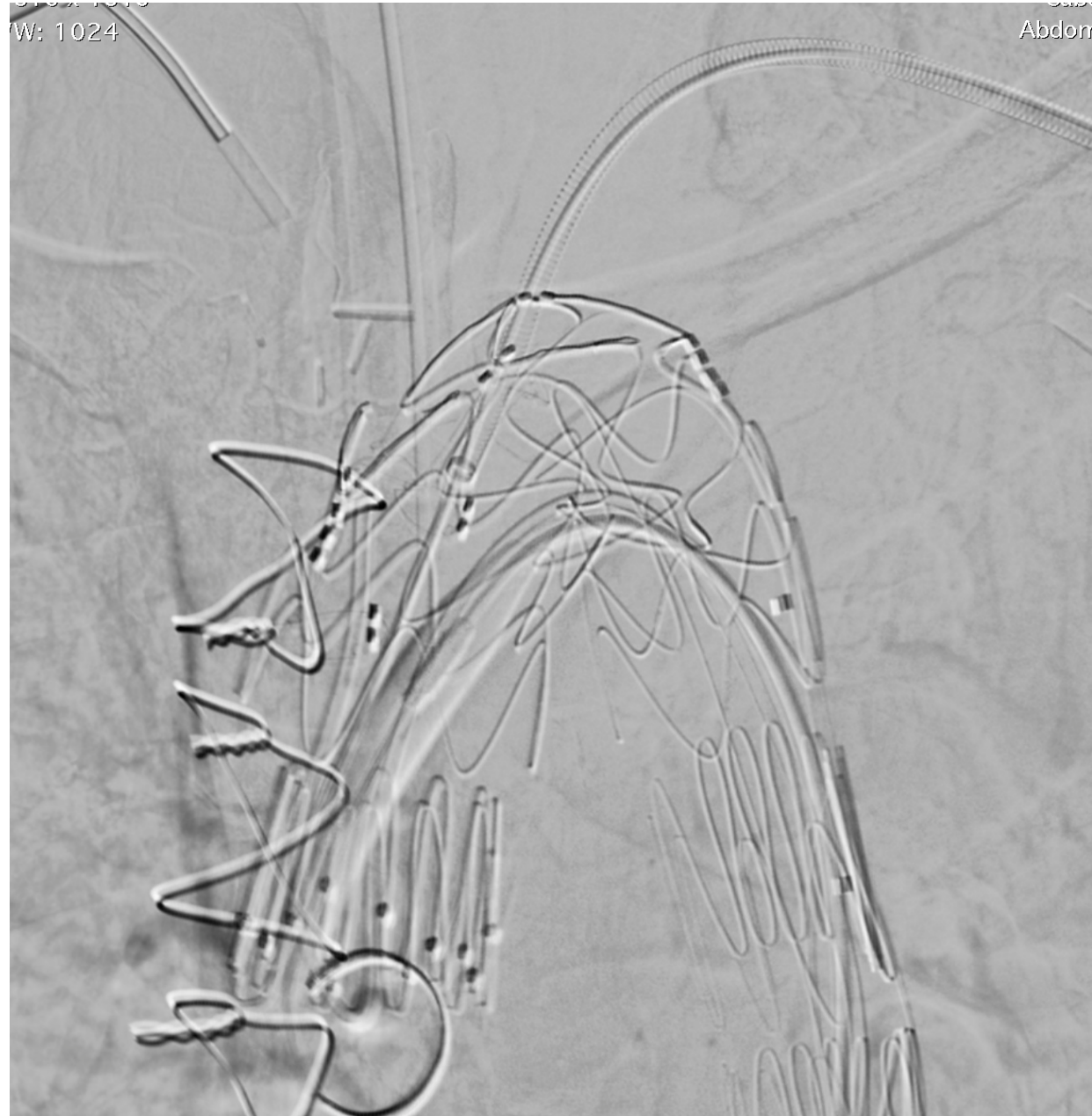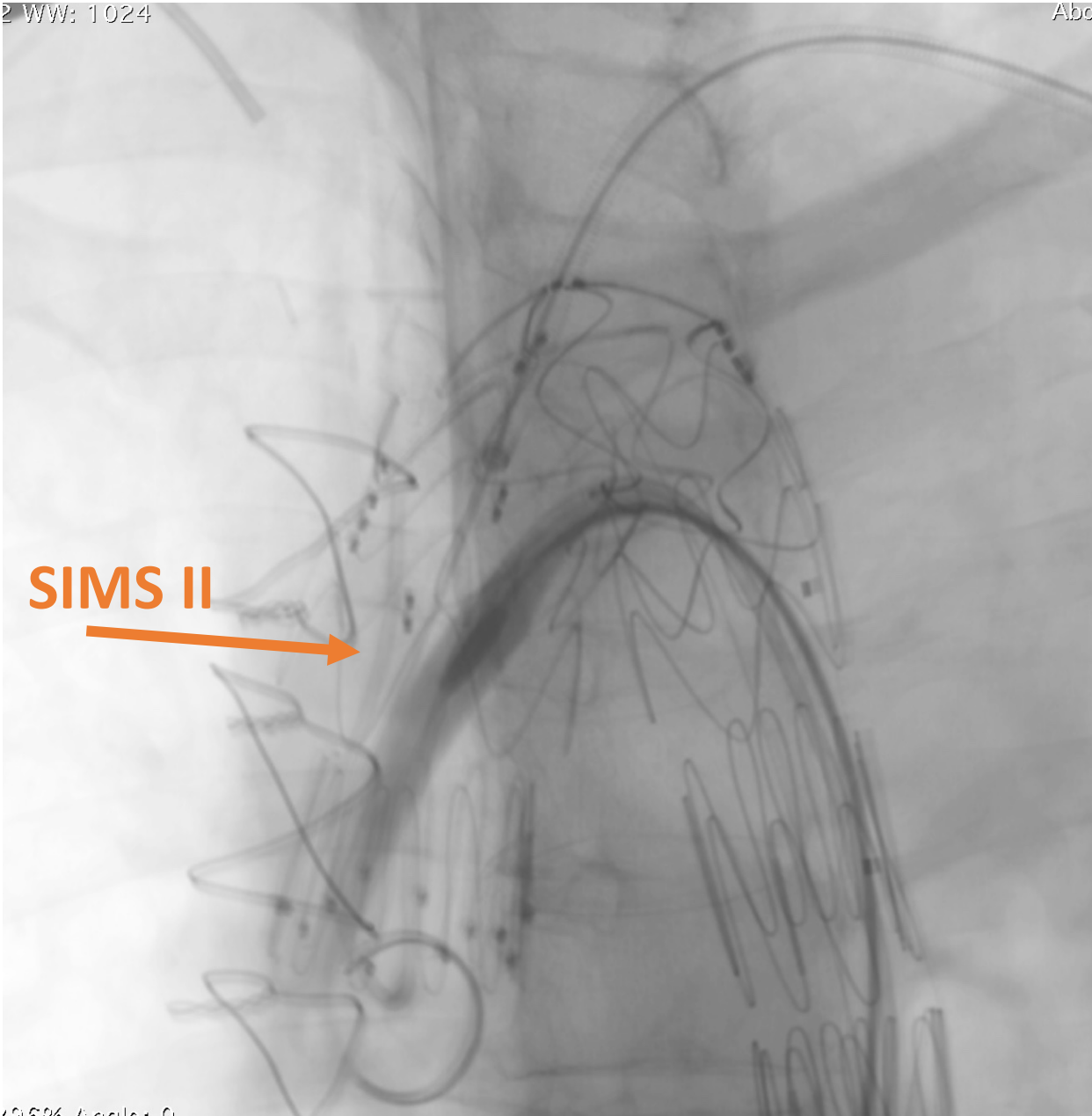
SIMS II



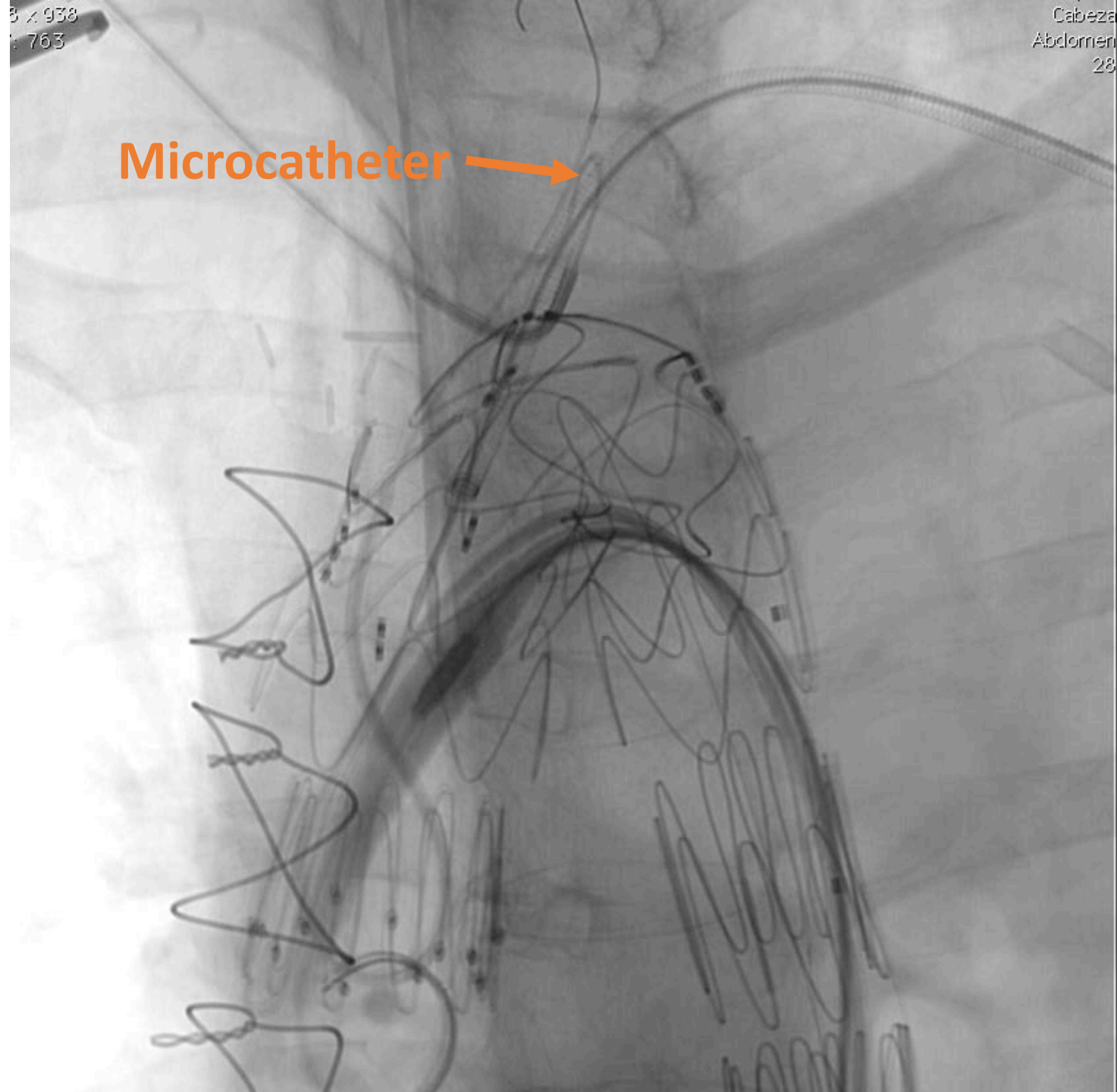
SIMS II



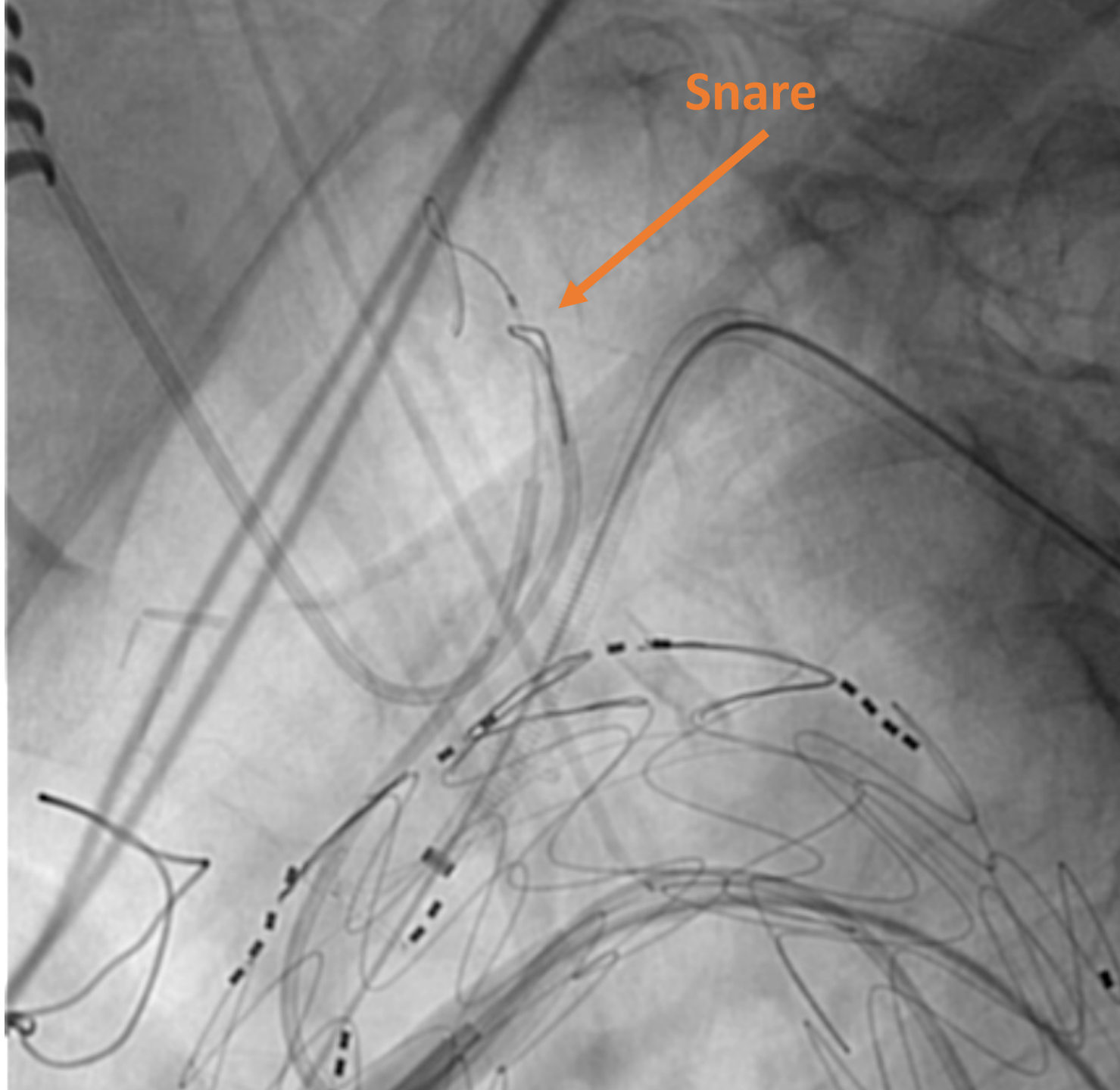

SIMS II

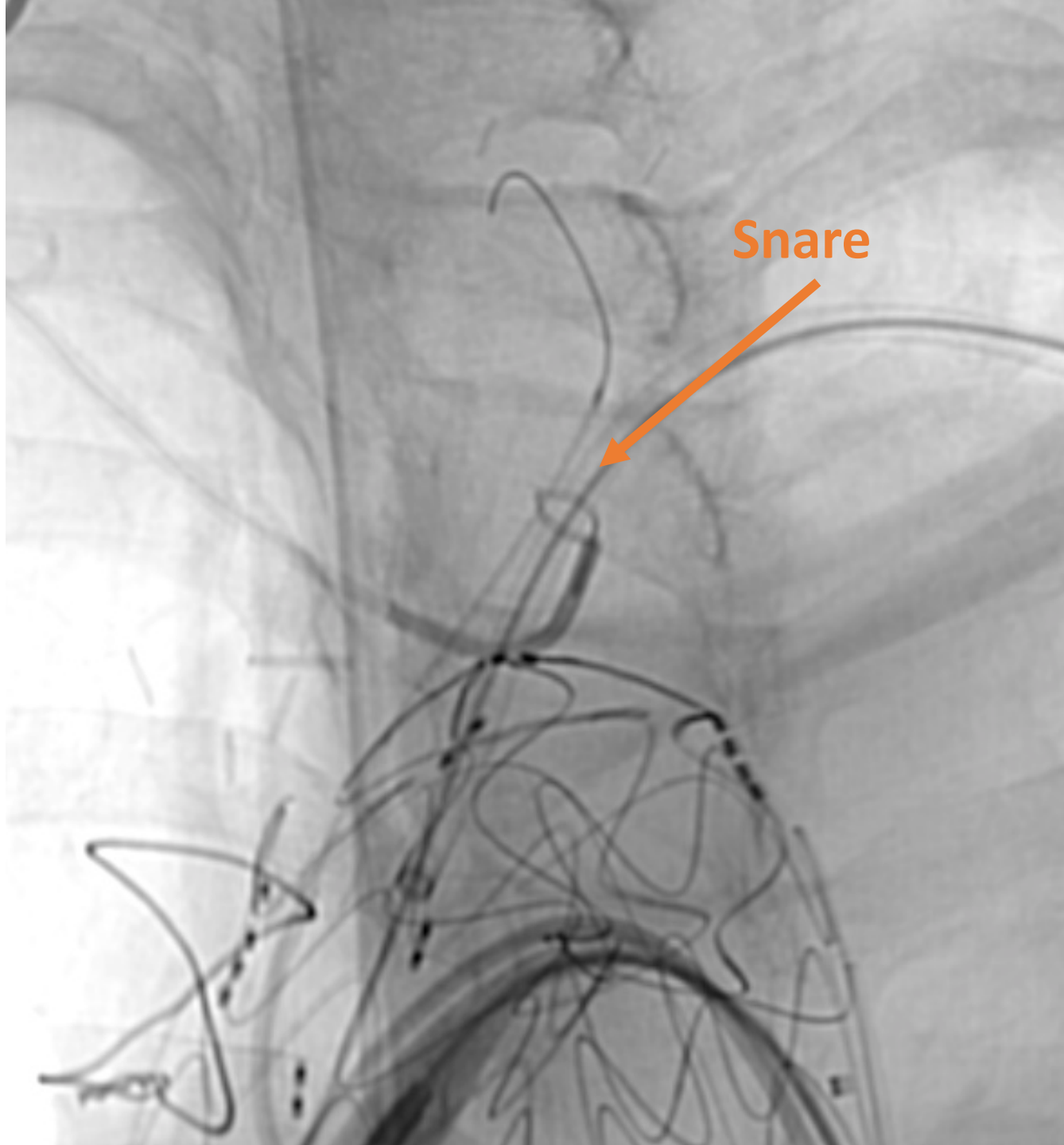


Microcatheter →

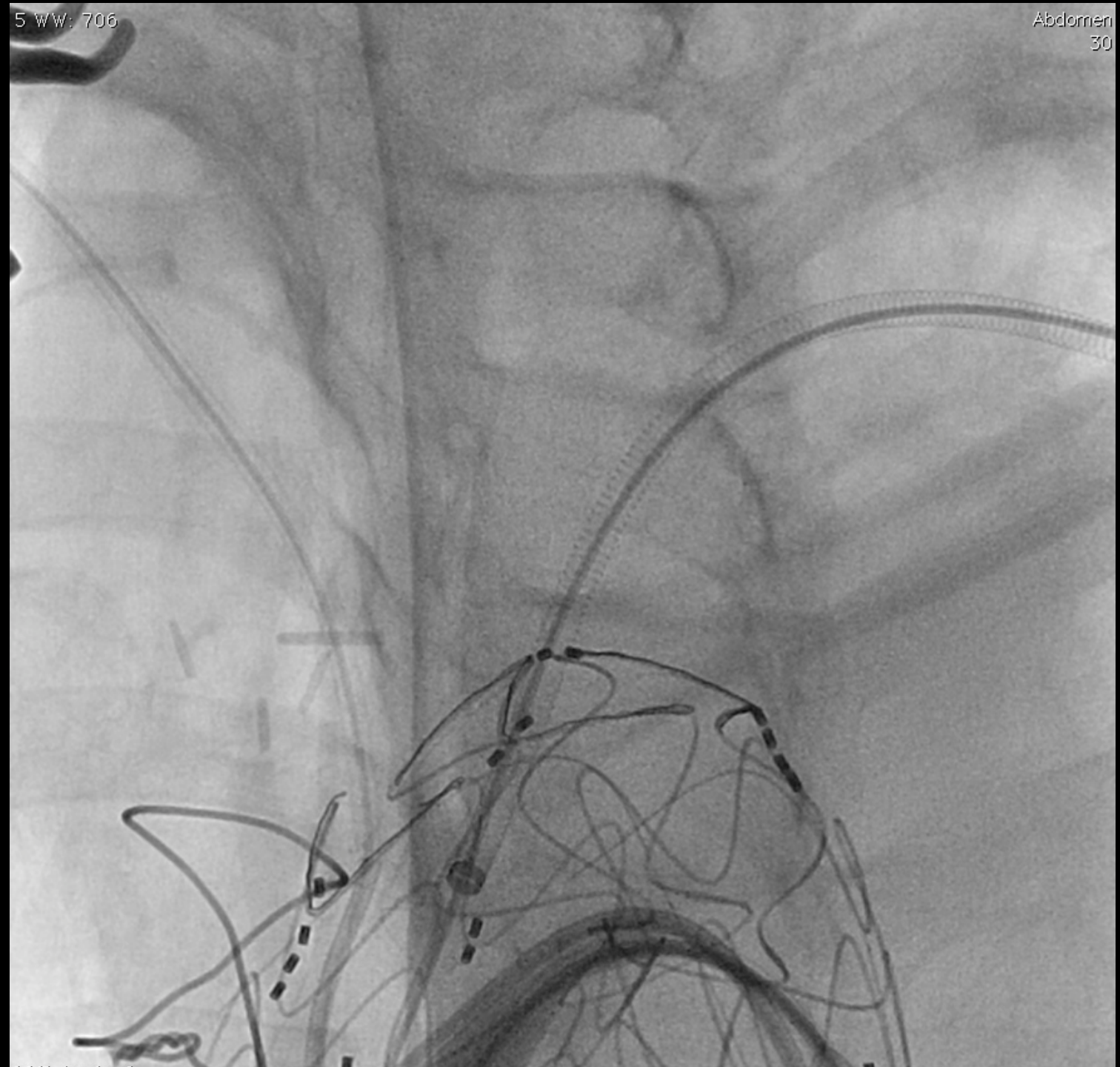


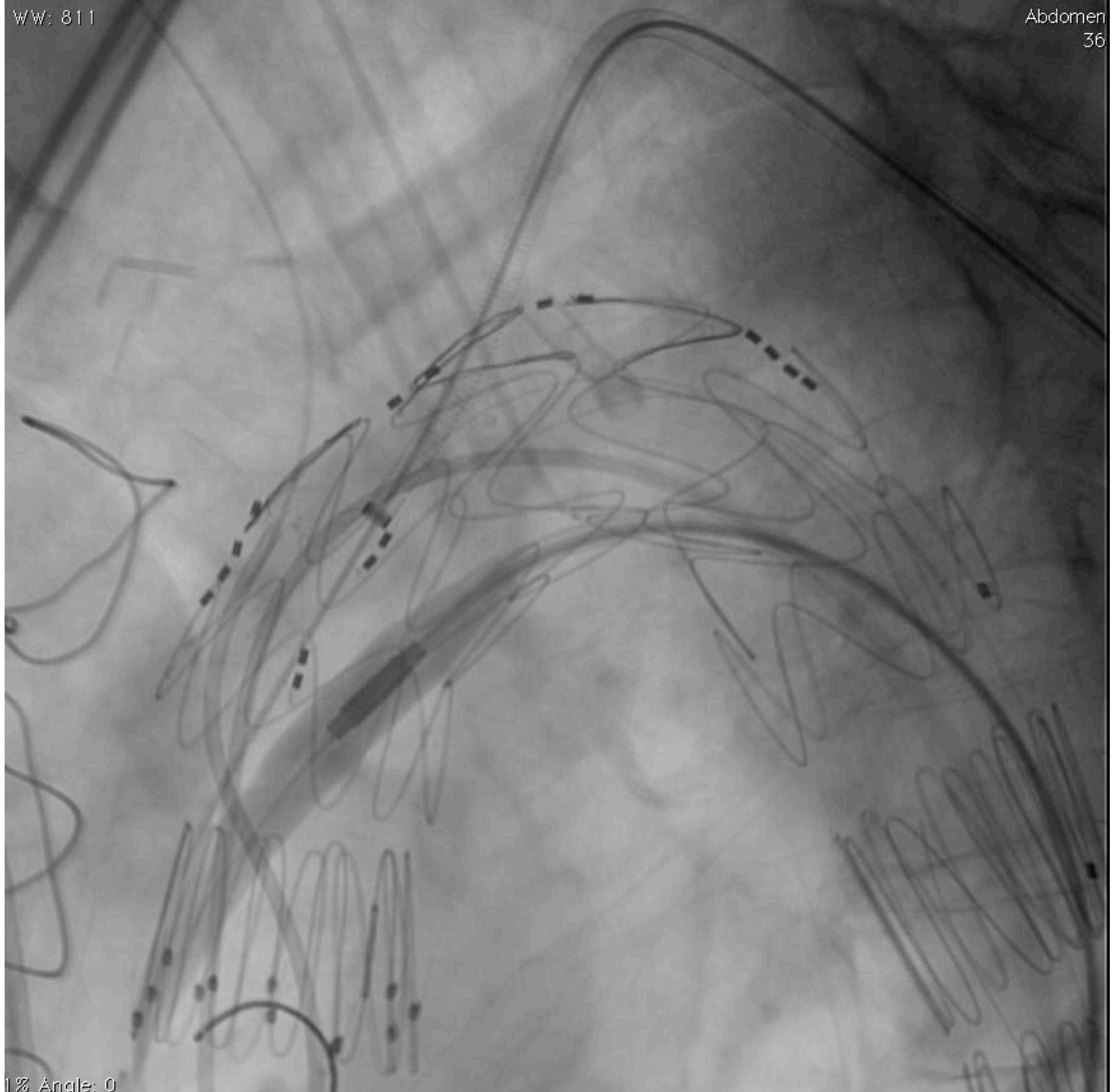Snare

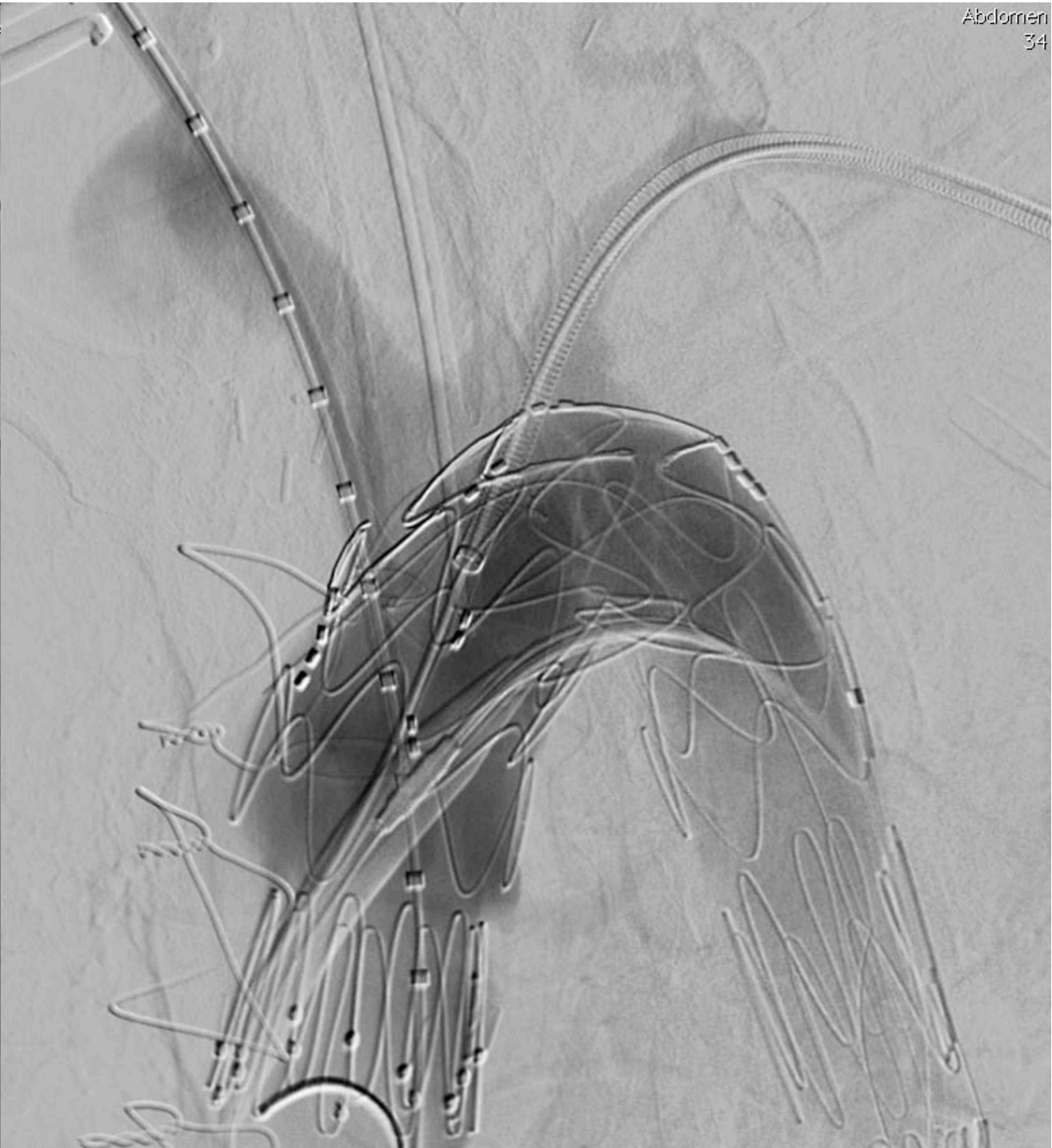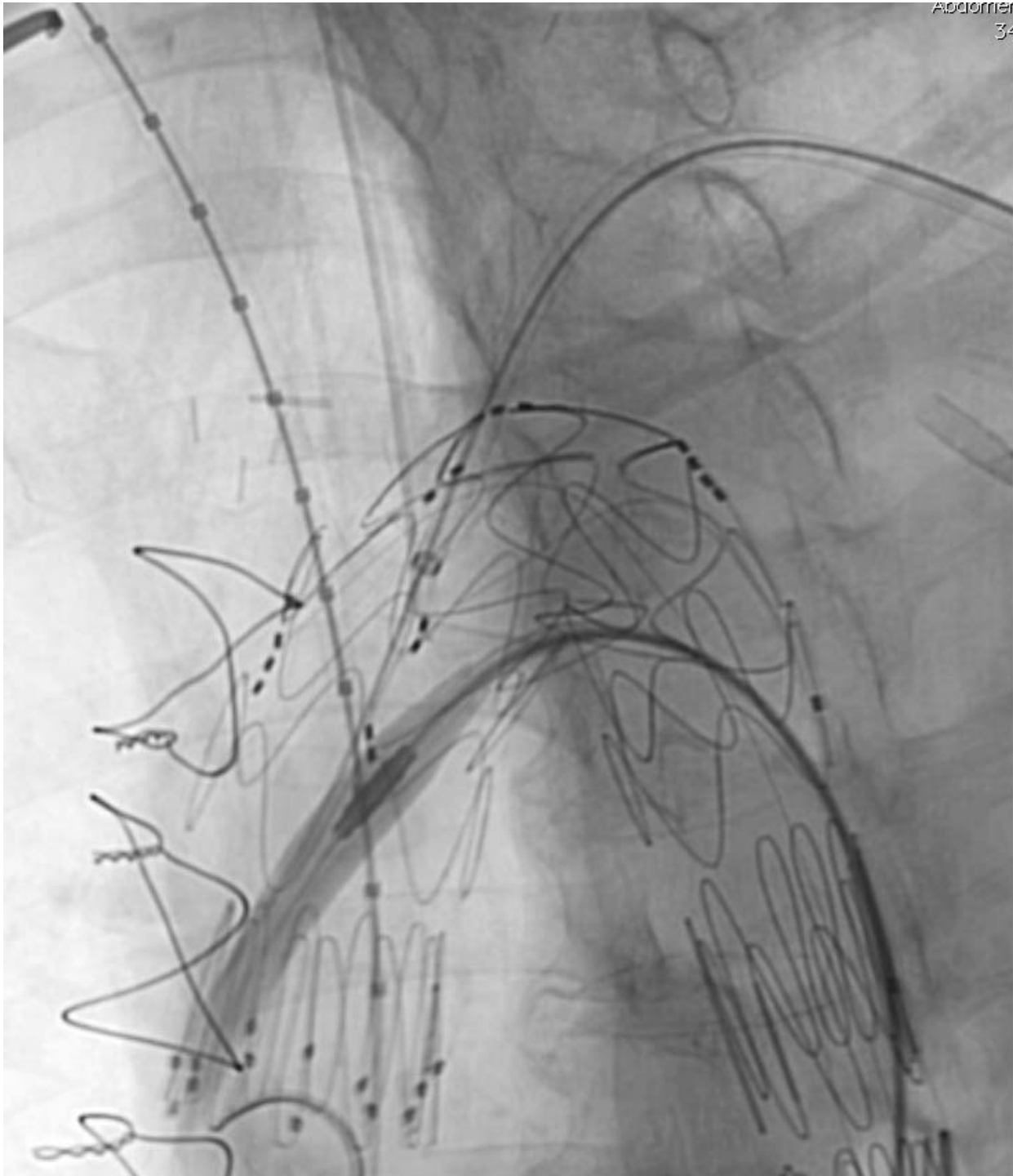


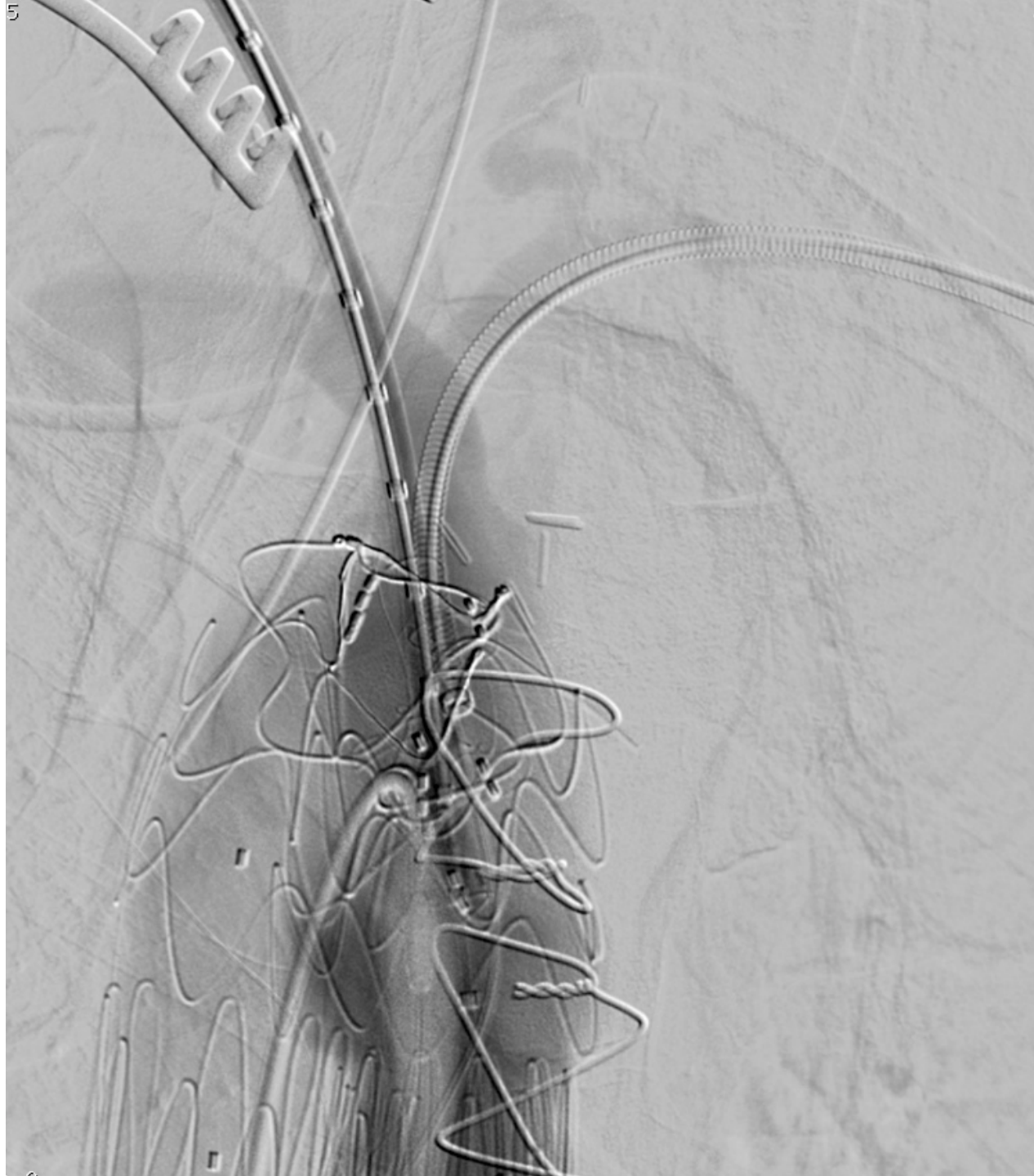


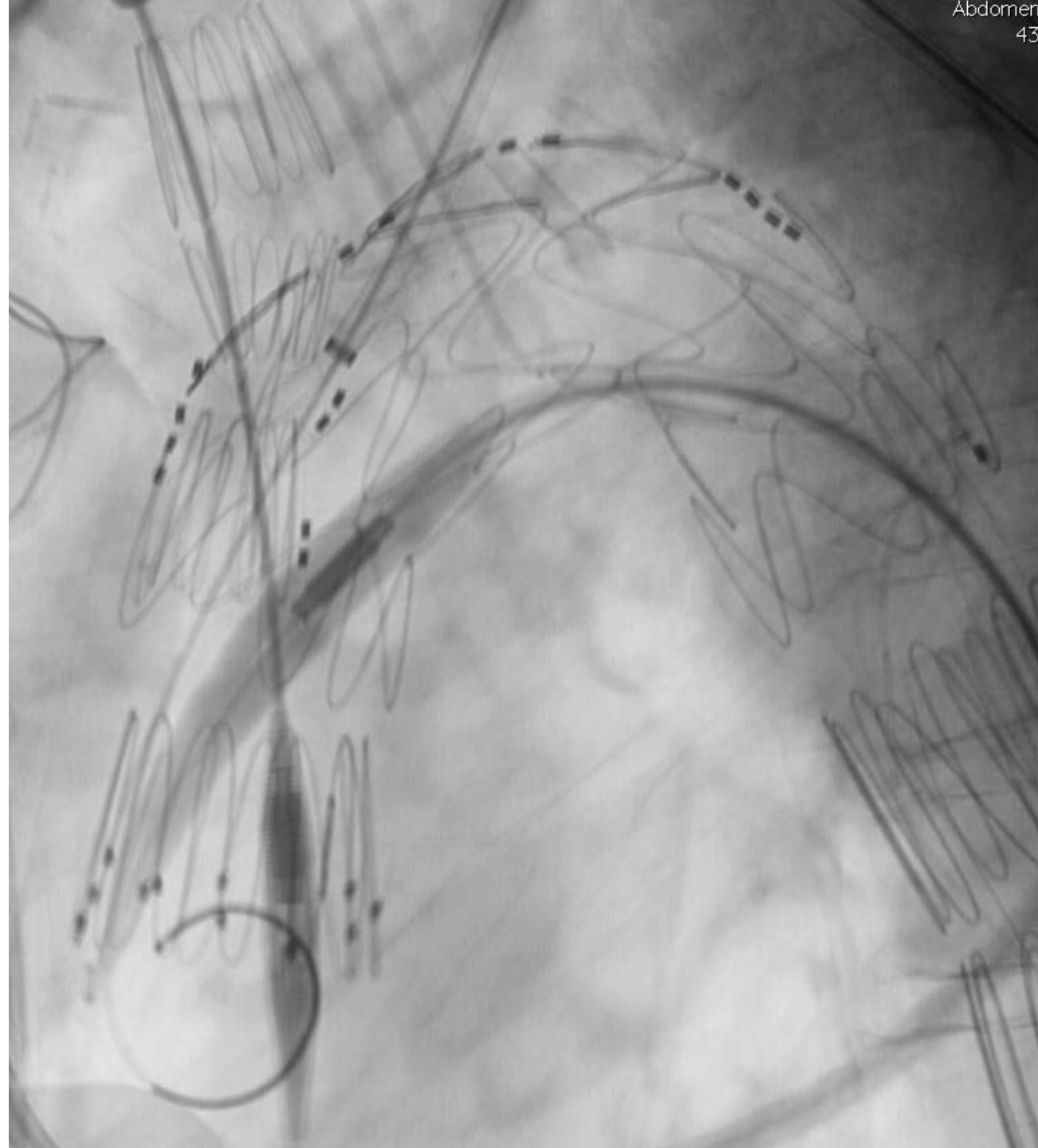
Snare

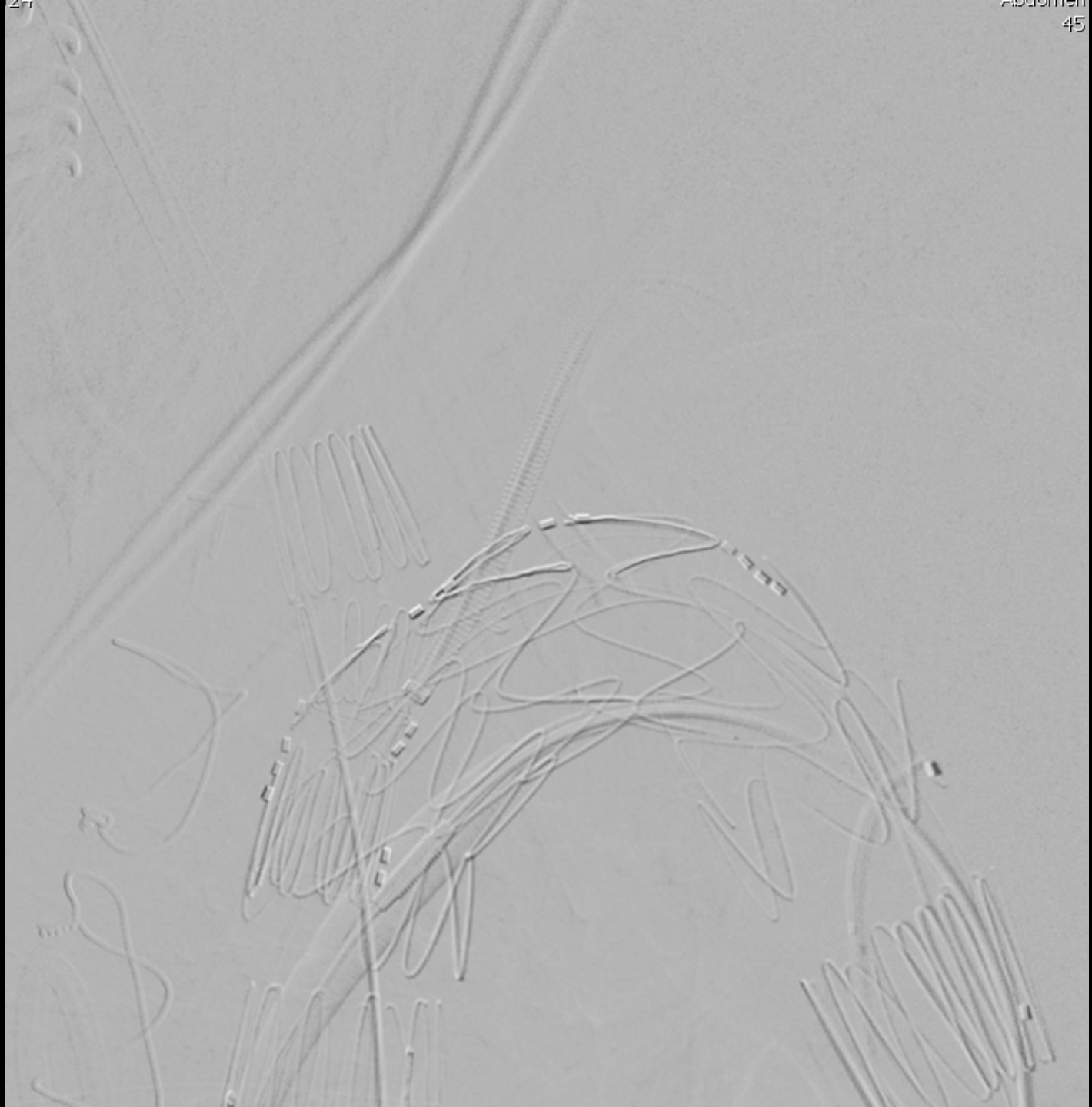


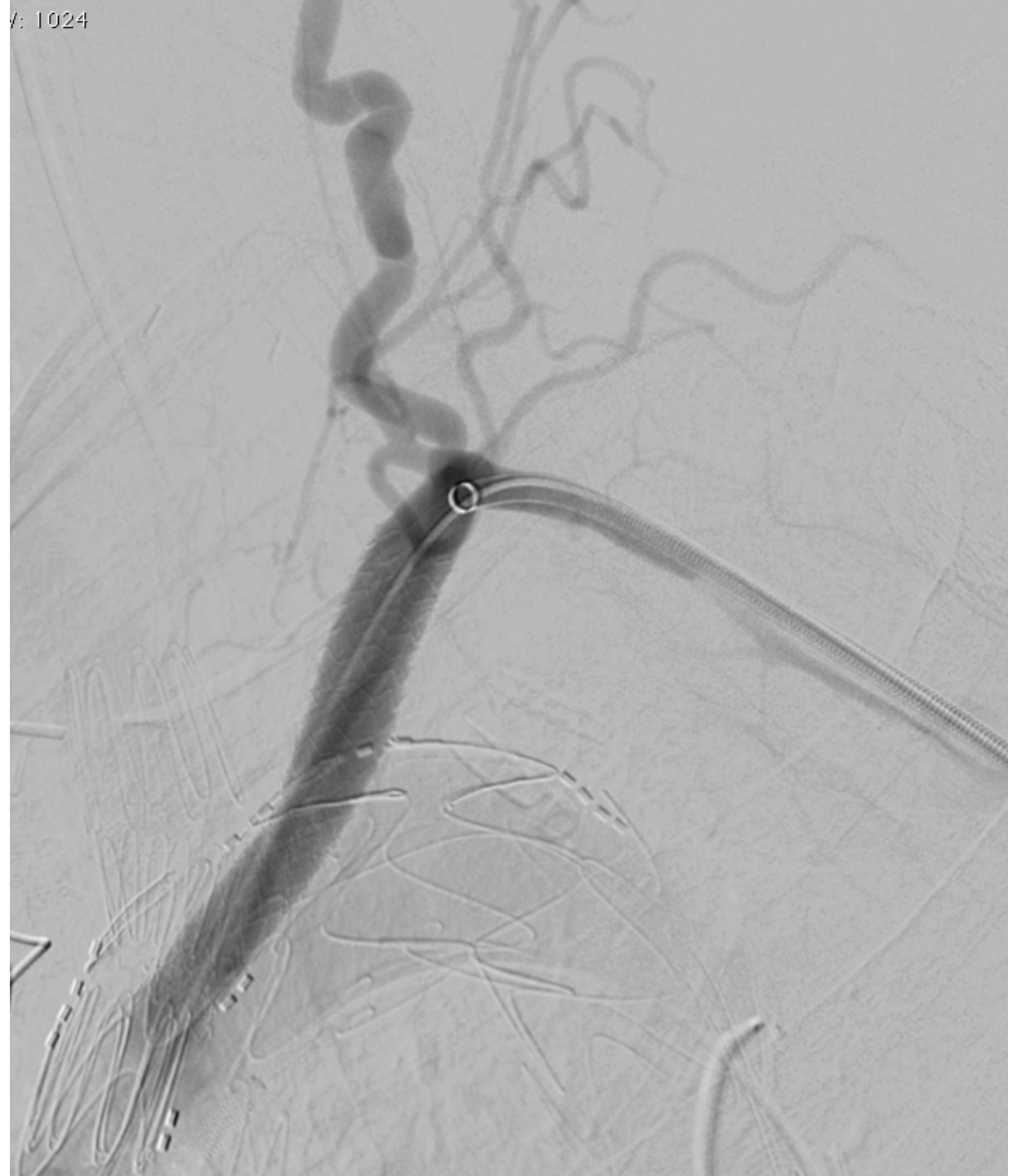
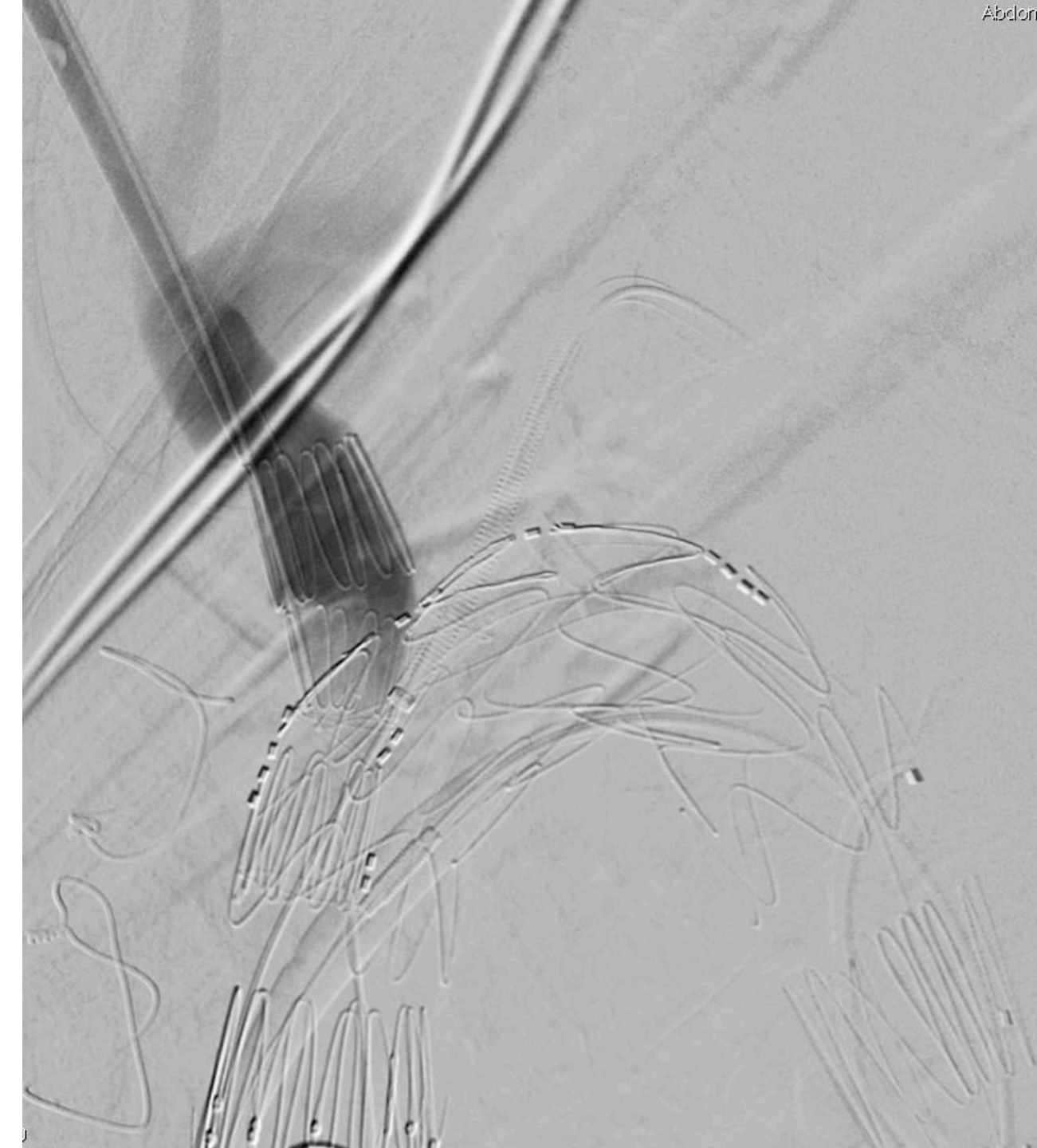












UT SOUTHWESTERN MEDICAL CENTER

