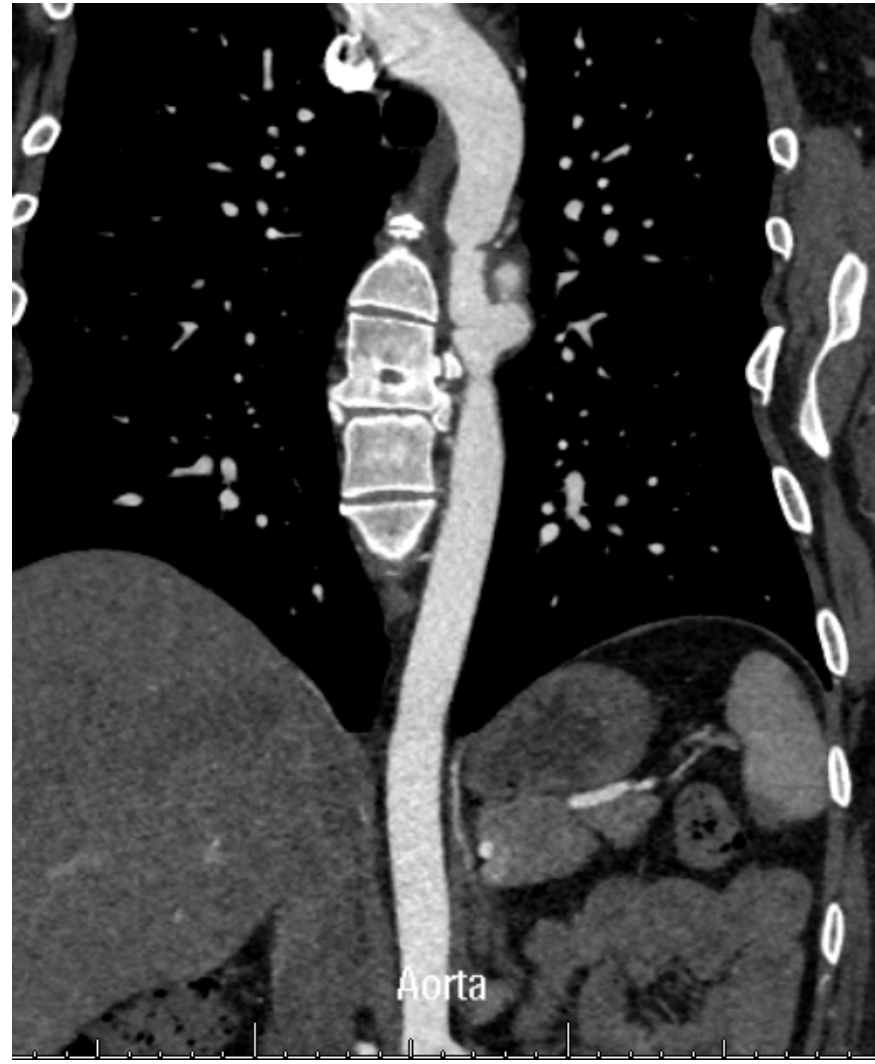
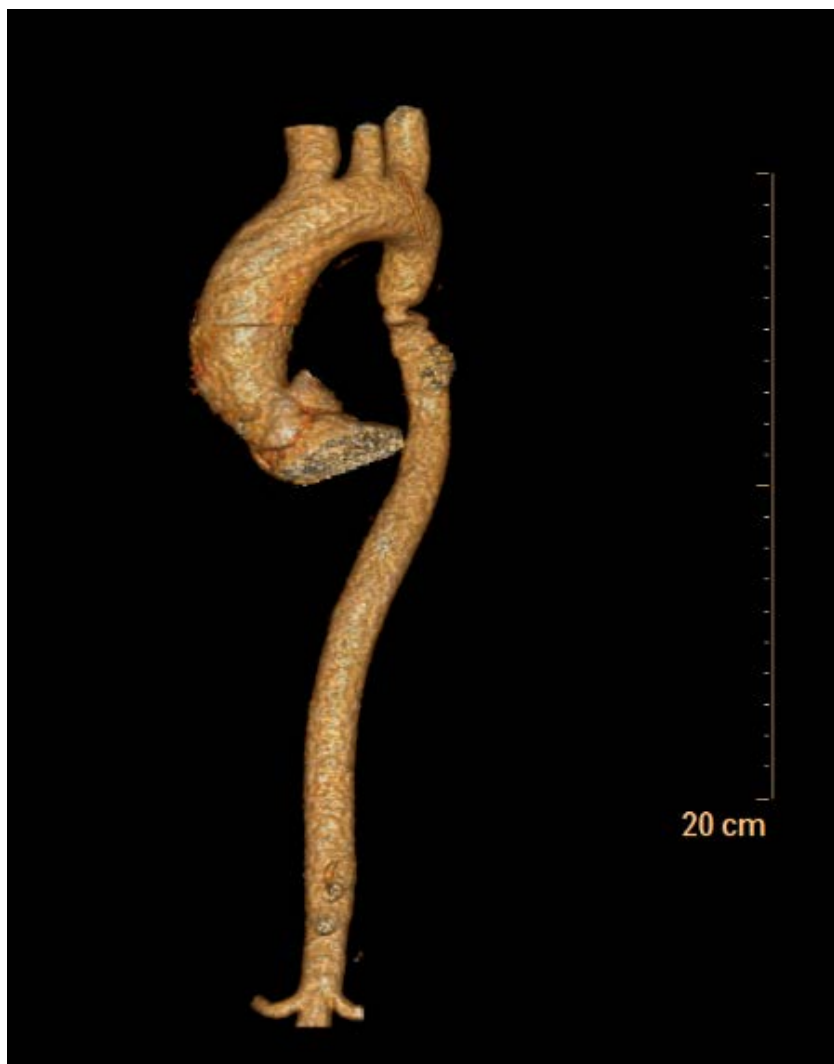
Type 3B Endoleak

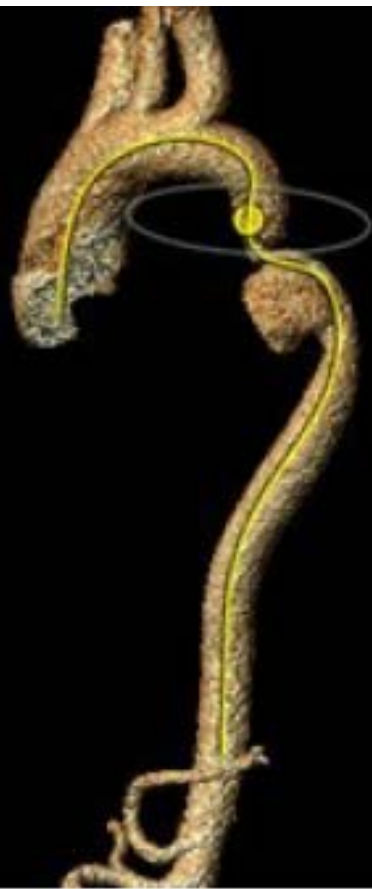Ross Milner, MD
Professor of Surgery
September 7, 2017

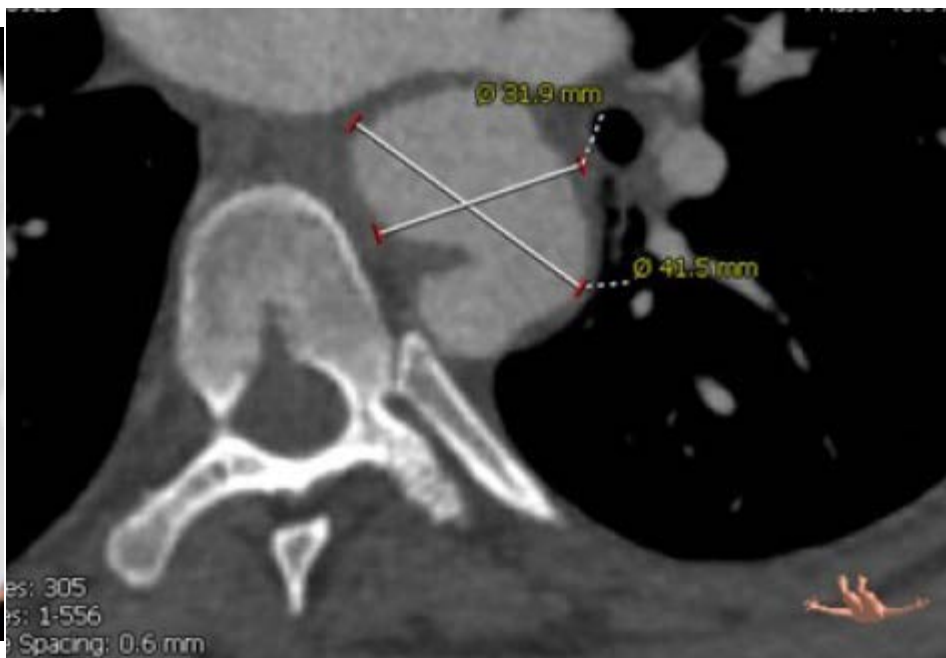
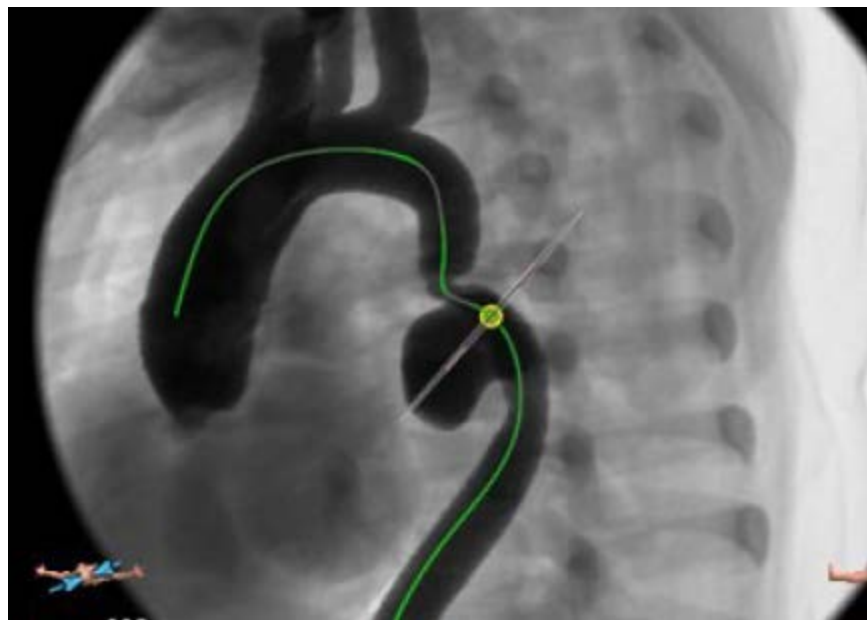History

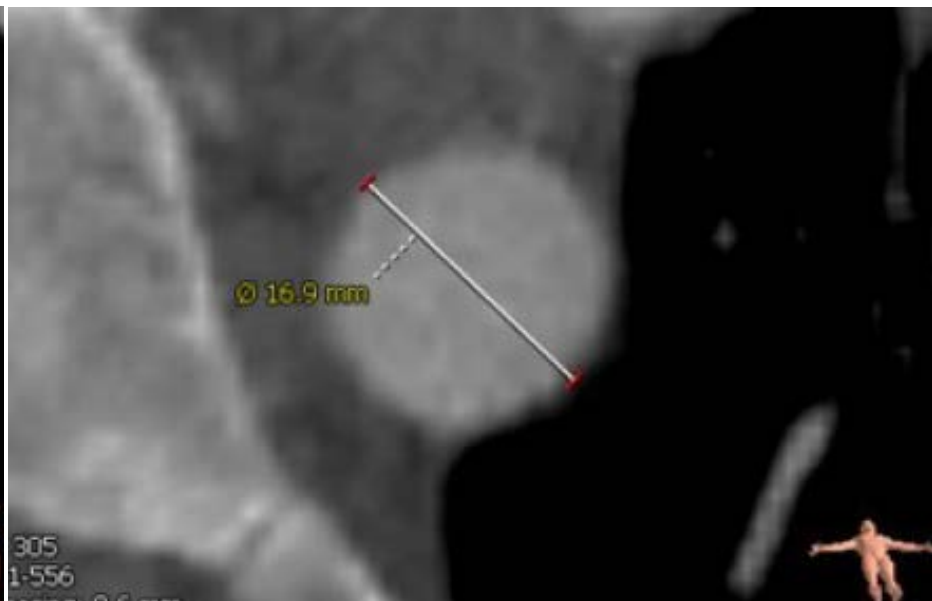
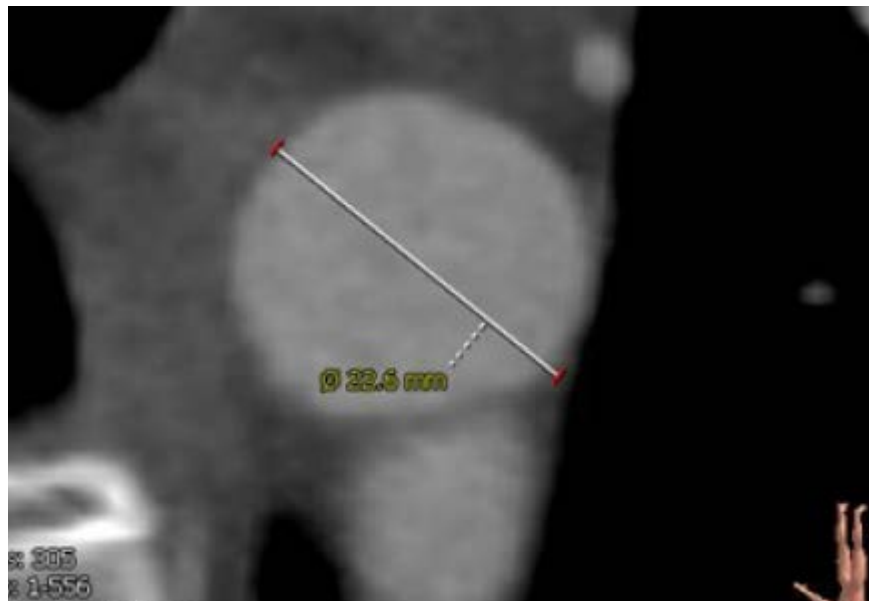- 34-year old woman with a known aortic coarctation (diagnosed at 16)
- Hypertension (2 meds) and mild renal insufficiency
- “My only option is open surgery”
- Decreased femoral pulses



LAO: 84°
Cranial: 0°







Hybrid OR

Im: 1/22
Se: 3

9/27/1982 F
University of Chicago
1
EVAR/TEVAR
CARE Body.4

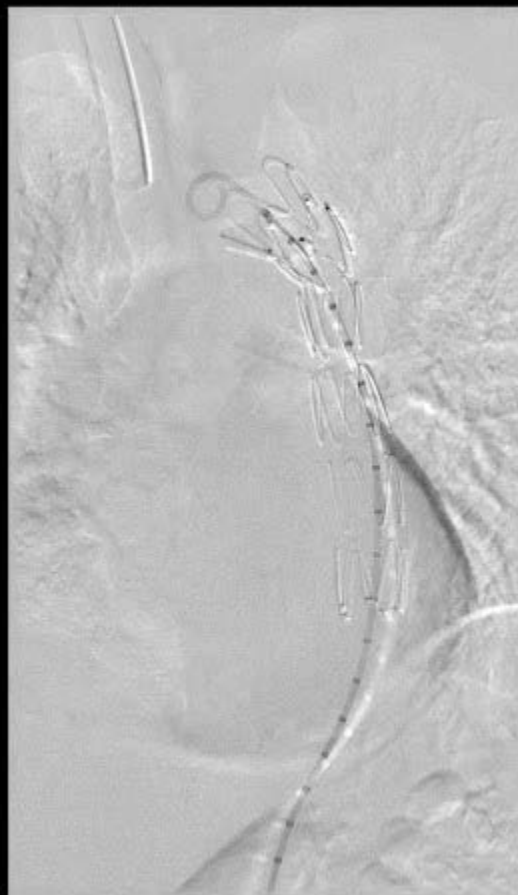
WL: 2047 WW: 4095 [D]
LAO: 40 CRA: 1

7/31/2017 10:52:11 AM

Device and Treatment

- Pre-dilate with 8 mm PTA balloon (8 Atm)
- 24 mm x 105 mm Zenith Alpha (16 Fr)
- Serial Dilation to maximum of 14 mm (Conquest balloon)
- Elimination of pressure gradient/exclusion of pseudoaneurysm

Im: 1/23
Se: 5



9/27/1982 F
University of Chicago
1
EVAR/TEVAR
CARE Body.4

WL: 2047 WW: 4095 [D]
LAO: 40 CRA: 1

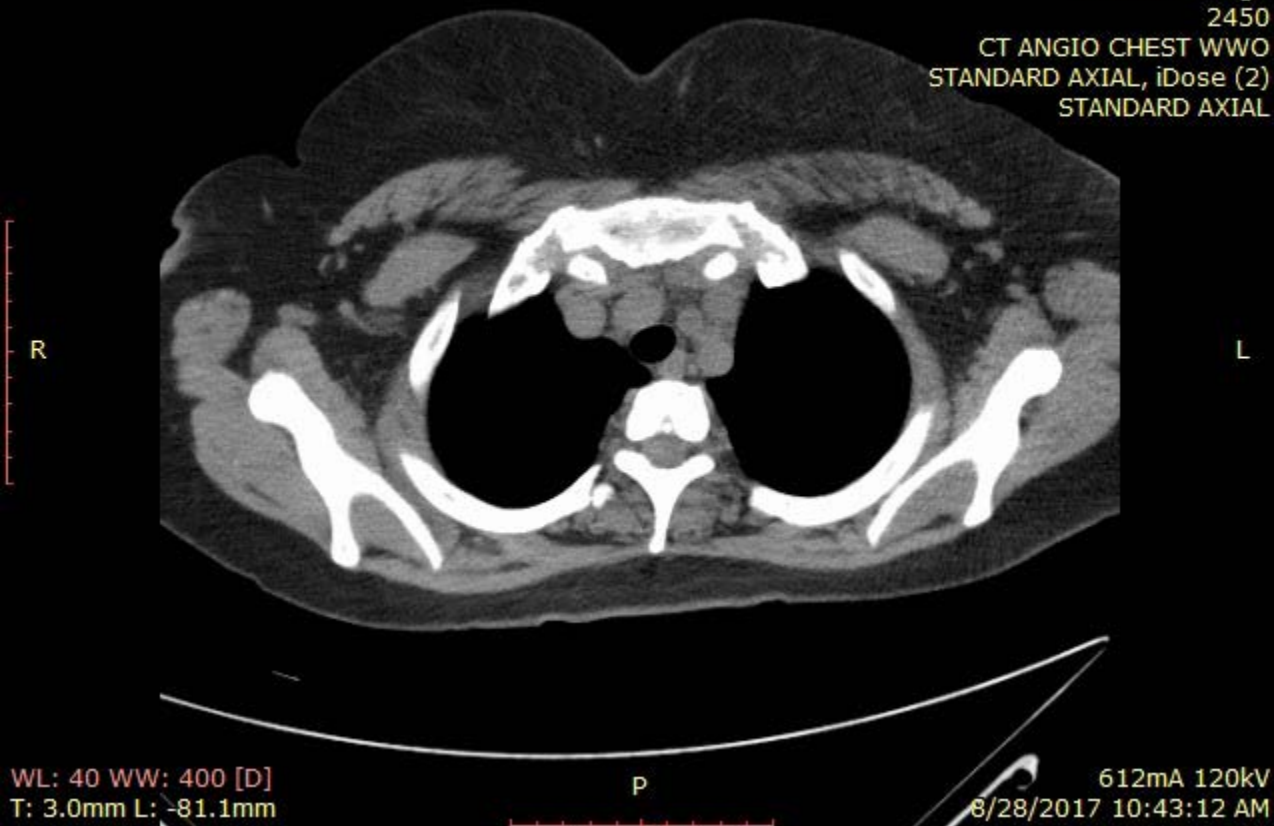7/31/2017 11:19:20 AM

One month Imaging

Im: 17/100
Se: 201

A

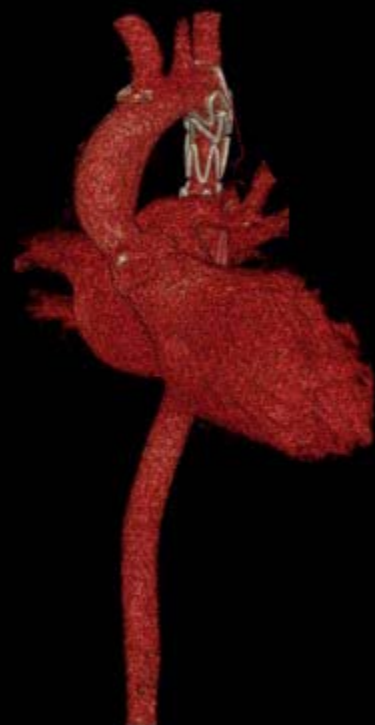9/27/1982 F
Univ of Chicago
2450
CT ANGIO CHEST WWO
STANDARD AXIAL, iDose (2)
STANDARD AXIAL



Im: 1/20
Se: 705

9/27/1982 F

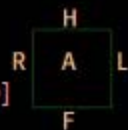2450
CT ANGIO CHEST WWO
3D
3D



R



10 cm



WL: 128 WW: 256 [D]

8/28/2017 10:39:18 AM

Im: 1/20
Se: 706

9/27/1982 F

2450
CT ANGIO CHEST WWO
3D
3D

R



10 cm

WL: 128 WW: 256 [D]



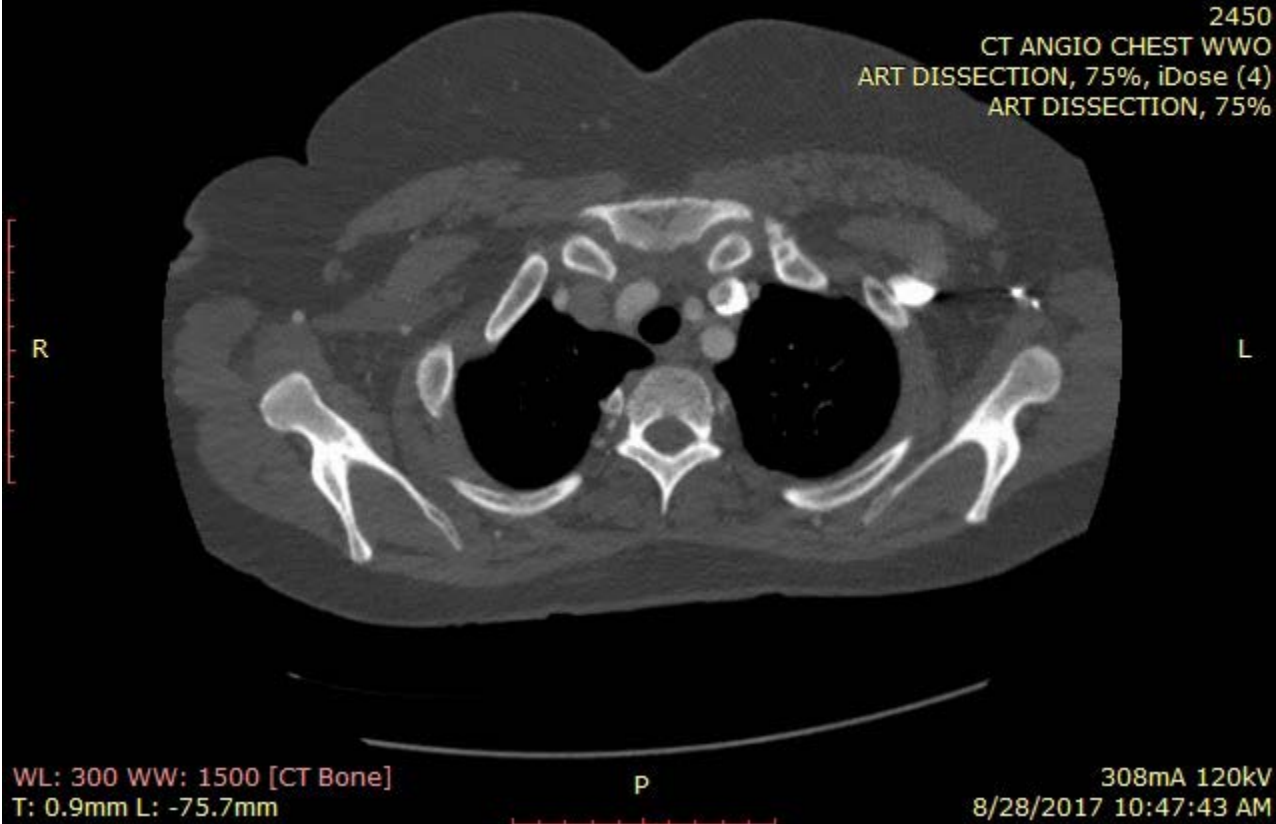F

8/28/2017 10:39:18 AM

Im: 98/719
Se: 701

A

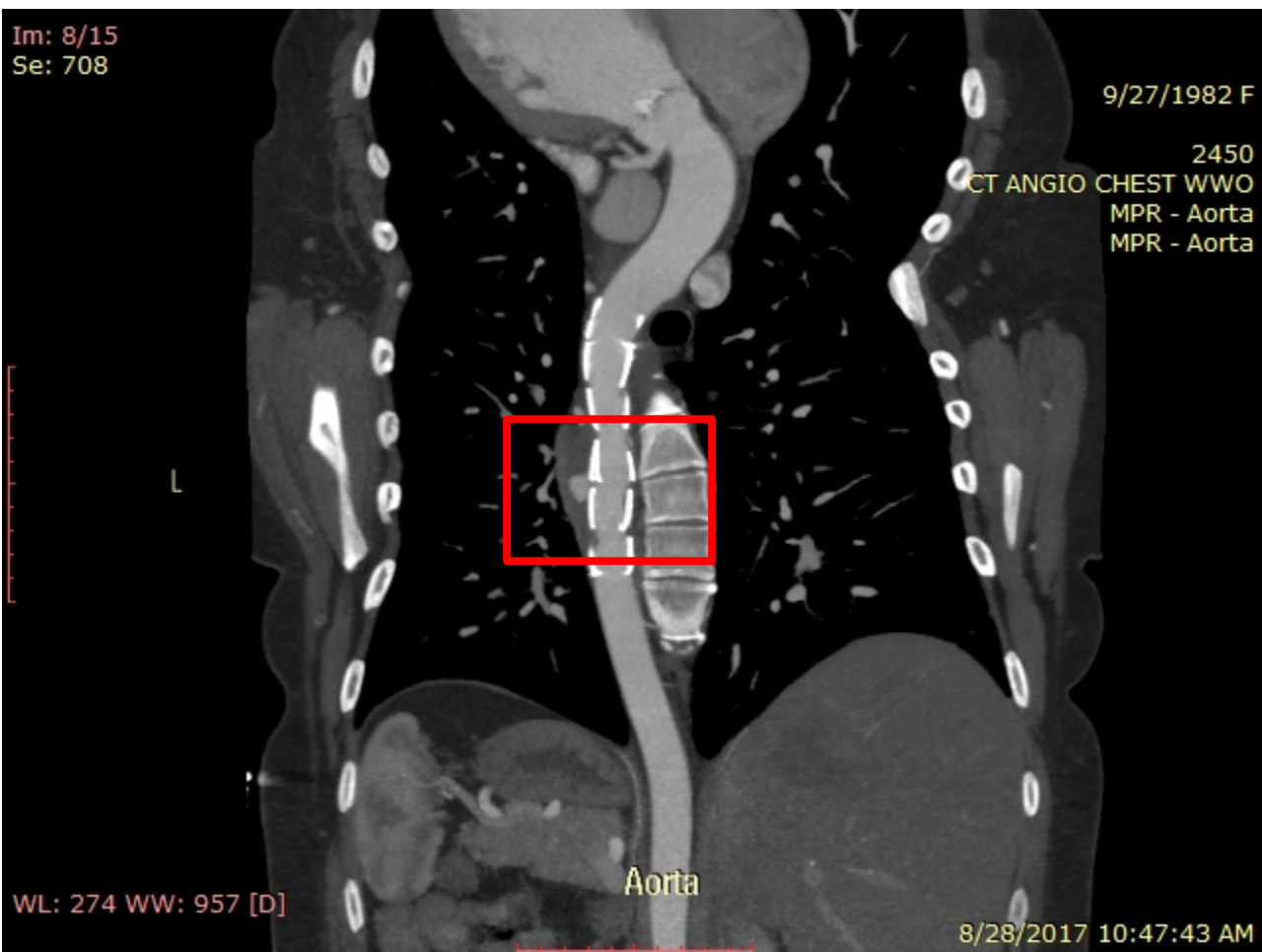
9/27/1982 F
Univ of Chicago
2450
CT ANGIO CHEST WWO
ART DISSECTION, 75%, iDose (4)
ART DISSECTION, 75%

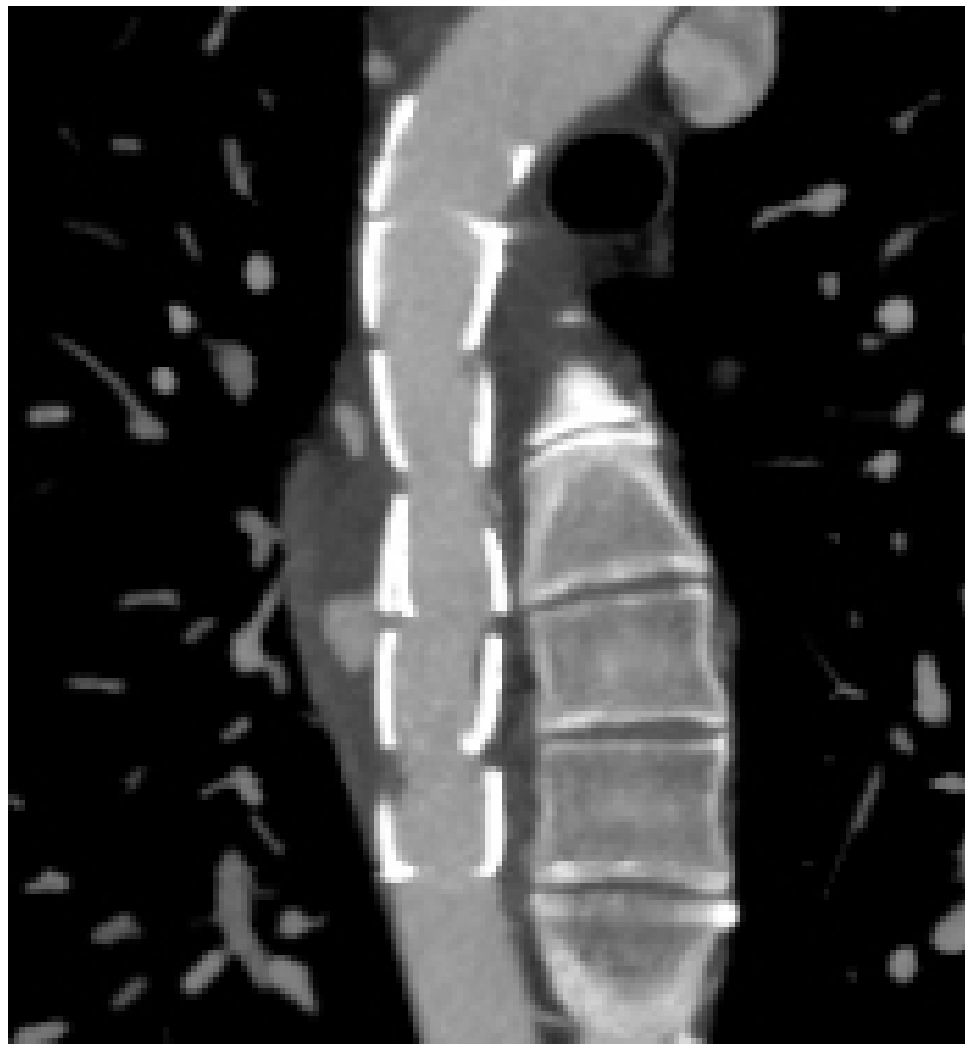

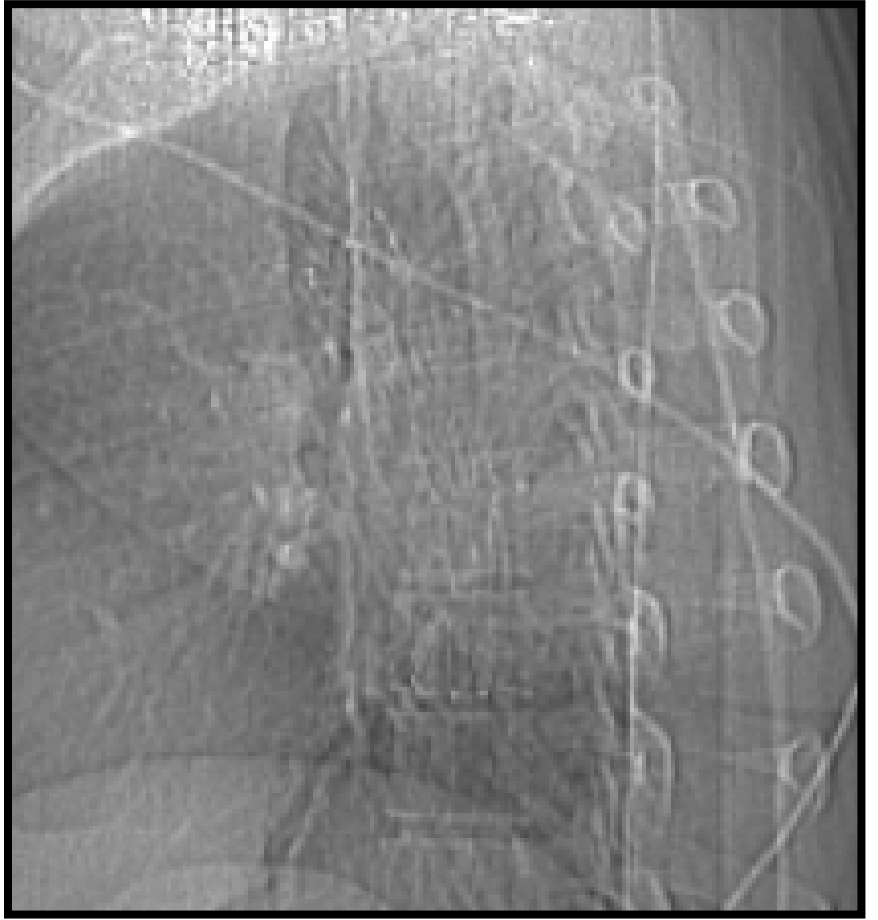
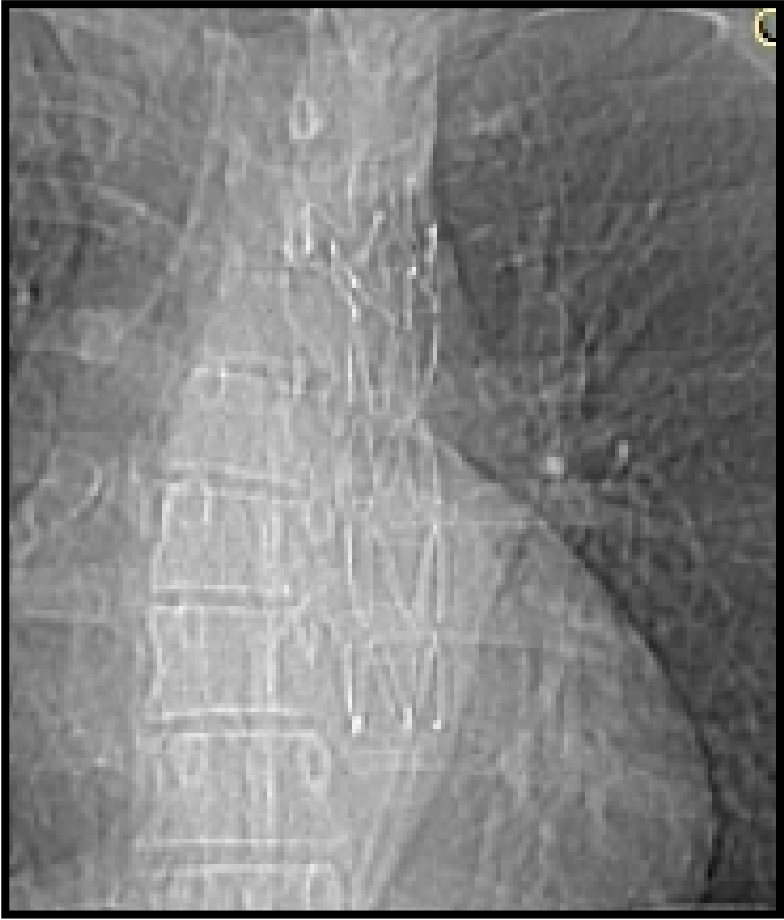Im: 8/15
Se: 708

9/27/1982 F

2450
CT ANGIO CHEST WWO
MPR - Aorta
MPR - Aorta







Next Steps?

Analysis

- No evidence of fracture
- Mostly excluded pseudoaneurysm

Analysis

- No evidence of fracture
- Mostly excluded pseudoaneurysm
- **Reline?**