

Beyond the Semen Analysis: New Tests in Male Infertility

Edmund Sabanegh, M.D., and Ashok Agarwal, Ph.D.

Sophisticated new tests that evaluate sperm function and genetics are taking male infertility evaluation to a new level.

While the semen analysis remains the cornerstone for a male fertility evaluation, it has limitations that mean it does not always accurately predict fertility. With the availability of tests that provide more in-depth information regarding sperm quality, Cleveland Clinic reproductive medicine specialists now can provide better diagnostic information for patients allowing more effective therapy.

The reactive oxygen species (ROS) test, one of the newest resources available, detects the presence of free radicals in the sperm. This is significant because polyunsaturated fatty acids in the plasma membrane of sperm cells are highly susceptible to damage by reactive oxygen species such as the superoxide anion, hydroxyl radical and hypochlorite radical. Oxidative stress results due to an imbalance in the amount of oxidants and antioxidants. This can degrade sperm quality by affecting sperm morphology and motility, cause fragmentation of the DNA or affect the sperm's ability to fertilize an egg.

Approximately 5 to 10 percent of infertile males will have normal semen analysis testing and no obvious etiology for their infertility. The ROS test is particularly useful in these men to detect the presence of oxidative stress in the sperm

Key Points

The reactive oxygen species (ROS) test – one of the newest resources available – detects the presence of free radicals in the sperm. Polyunsaturated fatty acids in the plasma membrane of sperm cells are highly susceptible to damage by ROS.

When the problem of ROS is identified through testing, treatments may help resolve the problem and improve fertility.

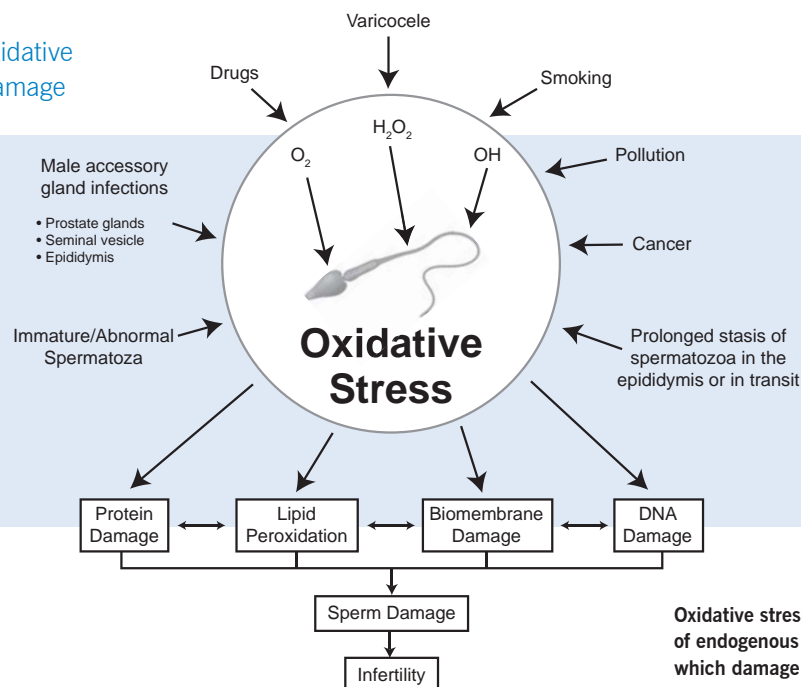
Sperm DNA testing also has assumed a very important role in a selected group of infertile men.

as a potential cause of infertility. The test is also appropriate in men with varicoceles, infections or occupational exposure to toxins such as lead or cadmium, all of which are linked to excessive ROS production.

Published studies have reported that oxidative stress may play a role in as high as 40 percent of male infertility. When the problem of ROS is identified through testing, supplementation with antioxidants and other treatments may help resolve the problem and improve fertility.

New genetic tests have furthered our understanding of male infertility and allow targeted therapy. These tests detect abnormalities in the number of chromosomes,

Mechanism of oxidative stress induced damage



Oxidative stress is derived from a variety of endogenous and exogenous sources, which damage cellular proteins as well as nuclear content.

microdeletions or translocations in the Y chromosome, or the presence of specific gene mutations such as the cystic fibrosis gene mutation. The latter is associated with obstruction of or lack of the vas deferens.

DNA defects in sperm inhibit male fertility and can also affect the success of assisted reproductive techniques. For this reason, sperm DNA testing has assumed a very important role in a selected group of infertile men.

The sperm chromatin structure assay is one of the few techniques for evaluating DNA integrity within the sperm cells. At Cleveland Clinic, we recommend this assay in women who have had repeated miscarriages as well as men whose semen analysis reveals marked morphological abnormalities or whose semen is normal but fertilization is unsuccessful.

These tests should be applied selectively, based on semen analysis results, the couple's history of infertility and the family medical history. Used appropriately, these novel tests now allow for evaluation of the functional quality of sperm when semen analysis alone is insufficient for predicting fertility. This information allows us to tailor therapy, thus expanding a couple's reproductive options and increasing their chances for success. ■

Penile Prosthesis Implantation after Radical Prostatectomy

Drogo Montague, M.D.

In the era of PSA screening for the early detection of prostate cancer, radical prostatectomy has become commonplace. Nerve sparing is not always advisable and, when indicated, it is not always successful; hence erectile dysfunction (ED) following radical prostatectomy frequently occurs. ED occurring after radical prostatectomy responds less often to systemic therapy (PDE5 inhibitors) than does ED from other causes. In this setting penile prosthesis implantation is frequently considered.

The ideal penile prosthesis would result in a penis that appears as closely as possible to normal in both the flaccid and erect states. To do this, a large volume of fluid needs to be transferred into penile cylinders that expand to produce the erection. This same volume of fluid must be able to leave the penis to permit penile flaccidity. To accomplish this, the large-volume fluid reservoir of a three-piece inflatable penile prosthesis is necessary. The most common location for this reser-

Key Points

When men face penile prosthesis implantation after radical prostatectomy, the three-piece inflatable penile prosthesis can be safely implanted and need not be avoided.

voir is the prevesicle space, and entry into this space is achieved by blindly puncturing the lower abdominal fascia through the single penoscrotal incision.

Because this fascia is scarred following radical retropubic prostatectomy, many avoid considering three-piece inflatable prosthesis implantation for this indication. A recent review of our experience with 942 consecutive patients undergoing penile prosthesis implantation in our institute revealed that 115 had ED following radical retropubic prostatectomy. In each of these patients the fascia could be blindly penetrated through the penoscrotal incision allowing successful reservoir implantation into the prevesicle space without injury to surrounding structures. Comparison of outcomes between this post radical prostatectomy cohort and the remainder of the implant recipients showed no significant differences. ■