

# Ovarian function preservation in the cancer patient

Tommaso Falcone, M.D., Marjan Attaran, M.D., Mohamed A. Bedaiwy, M.D., and Jeffery M. Goldberg, M.D.

Department of Obstetrics and Gynecology, Cleveland Clinic Foundation, Cleveland, Ohio

**Objective:** To review the clinical modalities that are available to women receiving potentially sterilizing cancer therapy.

**Design:** The MEDLINE database was reviewed for all publications on medication, surgery, or assisted reproductive technology that could potentially preserve fertility in women who are receiving cancer therapy.

**Conclusion(s):** There are many options available to a patient undergoing a treatment that will negatively impact her fertility. Many procedures and medical interventions have been proven successful both in terms of ovarian function and pregnancy rates. Other techniques have great potential but do not have long-term clinical data. It is important that the patient's primary care physician understand the methods available to preserve fertility in cancer patients and communicate this information to the patient. (Fertil Steril® 2004;81:243–57. © 2004 by American Society for Reproductive Medicine.)

**Key Words:** Ovarian transposition, ovarian function protection, ovarian transplantation

Survival rates for cancers that occur in women of reproductive age have improved dramatically. Preservation of fertility in these women has become a more relevant issue. Many treatments that are administered for childhood and adolescent cancers carry a substantial risk for future infertility. This risk varies according to the presenting pathology and requires preventive treatment. It was estimated that in 2000, one in 1,000 adults was a survivor of childhood cancer (1). This review will focus on the clinical modalities that are available to women receiving potentially sterilizing cancer therapy. The potential role of new techniques will also be assessed.

of cytotoxic drugs appears reversible in sites that contain rapidly dividing cells such as the gastrointestinal tract or bone marrow, it appears to be irreversible in the ovary. Histological sections of the ovary after exposure to cytotoxic drugs show a spectrum of changes ranging from decreased numbers of follicles to absent follicles to fibrosis (4). As survival rates continue to improve for young cancer patients, the reproductive consequence of exposure to chemotherapeutic agents becomes a significant concern.

The exact incidence of POF after chemotherapy is difficult to establish because many factors contribute to ovarian failure. Bines and colleagues (5) reviewed the effects of adjuvant chemotherapy in premenopausal women with breast cancer. They reported the rates of amenorrhea associated with different chemotherapeutic regimens and analyzed the variables that may have contributed to amenorrhea. Depending on the type of chemotherapy regimen used, the incidence of chemotherapy-related amenorrhea ranged from 0 to 100%. Rates of amenorrhea varied from 21%–71% in the younger age group to 49%–100% in the older age group. The risk of gonadal damage increases with the age of the female, most likely

## IMPACT OF CHEMOTHERAPY ON OVARIAN FUNCTION

Premature ovarian failure (POF) is a well-known consequence of exposing female gonads to chemotherapeutic drugs (2, 3). Patients are exposed to these agents during treatment of malignancies such as Hodgkin's disease, while undergoing adjuvant therapy for breast cancer, or during treatment for autoimmune diseases such as rheumatoid arthritis and systemic lupus erythematosus. Unfortunately, while the effect

Received May 13, 2003;  
revised and accepted  
June 23, 2003.

Reprint requests:  
Tommaso Falcone, M.D.,  
Department of Obstetrics  
and Gynecology, The  
Cleveland Clinic  
Foundation, 9500 Euclid  
Ave., A81, Cleveland, Ohio  
44195 (FAX: 216-445-5526;  
E-mail: falcont@ccf.org).

0015-0282/04/\$30.00  
doi:10.1016/j.fertnstert.2003.  
06.031

because older women have fewer oocytes than younger women.

The drug regimen (type, duration, and dose) also determines the likelihood of POF. Alkylating agents such as cyclophosphamide, L-phenylalanine mustard, and chlorambucil permanently damage gonadal tissue by interacting chemically with DNA. These agents cause inaccurate base pairing and produce single- and double-stranded breaks. Thus, DNA, RNA, and protein synthesis is inhibited. Agents that do not induce permanent ovarian failure include 5-fluorouracil, methotrexate, etoposide, and doxorubicin. In one study of seven women with osteosarcoma who were treated with methotrexate, there was no evidence of POF or gonadal dysfunction (6). Also, gonadal dysfunction has not been demonstrated in women who were treated with methotrexate for choriocarcinoma.

The close structural and functional relationship between granulosa cells and the oocyte makes it difficult to establish the exact target of cytotoxic drugs. Destroying either one leads to the demise of the other. These drugs may impair follicular maturation and/or deplete primordial follicles (4, 7). Temporary amenorrhea will result when maturing follicles are destroyed by cytotoxic drugs. Permanent amenorrhea or POF will result when all primordial follicles are destroyed. There are conflicting data regarding the sensitivity of the primordial follicle to cytotoxic drugs. The primordial follicles of the mouse are sensitive to cyclophosphamide, but those of the rat are not (8, 9). Because alkylating agents are not cell cycle specific, they may be able to act on both the oocyte and pregranulosa cells of the primordial follicles (10, 11).

The cumulative dose of the cytotoxic drug being administered is a key factor that affects permanent ovarian failure. Goldhirsch and colleagues (12) demonstrated a steadily increasing rate of POF ranging from 10% to 61% as the cumulative dose of cyclophosphamide increased. Younger women require higher cumulative doses of cytotoxic drugs than older women before amenorrhea is induced. In one study, the average dose of single-agent cyclophosphamide before the onset of amenorrhea was 5,200 mg in 40-year-old women, 9,300 mg in 30-year-old women, and 20,400 mg in 20 year-old women (13). These investigators also demonstrated that the "cumulative dose appears to be more important than the dose rate since administration of low daily doses of cyclophosphamide given over several months was only slightly less effective at inducing permanent ovarian failure than a high dose in 4 days" (13).

Finally, older women have a shorter duration to onset of amenorrhea after exposure to cytotoxic drugs. Bines et al.'s (5) review showed that women younger than 40 years of age experienced amenorrhea 6–16 months after initiation of chemotherapy, whereas women older than 40 experienced amenorrhea within 2–4 months. The effect of duration of treat-

ment and route of administration on gonadal toxicity is not yet clear.

The population of women who may potentially require gonadal protection against alkylating agents is quite large. Twenty-five percent of breast cancer is diagnosed in women who are under the age of 50. With the typical regimen of CMF (cyclophosphamide 11–15 grams, methotrexate, 5-fluorouracil), two-thirds of women will become amenorrheic. With the AC (doxorubicin, cyclophosphamide) protocol, 34% will be amenorrheic at 3 years. This percentage increases if taxanes (such as docetaxel) are also used with this regimen.

Prepubertal girls seem less susceptible than young women to cytotoxic drugs (14). Treatment with up to 50,000 mg of cyclophosphamide failed to induce ovarian failure in a population of girls (15). In this study, the mean time from completion of cyclophosphamide to the time of the study was approximately 15 years. The mean age at the time of treatment was 10.7 years. Nicosia et al. (16) showed that while the number of growing follicles demonstrated by gonadal histology at autopsy was reduced in patients receiving combination chemotherapy regimens, there was no significant change in the number of primordial follicles. This may explain why the prepubertal ovary is less susceptible to the effects of cytotoxic drugs.

Cyclophosphamide ovarian toxicity may be progressive in nature (4). The true incidence of POF in this population is unclear because long-term follow-up studies are rare (14, 17–20). Most of these studies have documented subsequent menarche and ovulatory cycles in these patients (17). When the outcome of subsequent pregnancies in these patients was reviewed, the frequency of congenital anomalies in the children born to them was not increased (21, 22).

## PHARMACOLOGIC PROTECTION

### Oral Contraceptive Pills

Based on the premise that cytotoxic drugs primarily damage maturing follicles, oral contraceptive pills (OCPs) were one of the first agents used to protect gonadal function. In a small number of patients, Chapman and Sutcliffe (23) demonstrated that women on OCPs and cytotoxic drugs had a larger number of follicles present per histological section than women not on concomitant OCPs. However, later studies were unable to demonstrate a protective effect on the ovary. Whitehead and colleagues (24) reported nine patients who were taking OCPs while undergoing chemotherapy. Amenorrhea developed in four of these patients, and three developed oligomenorrhea. Thus, perhaps because they suppress the gonads incompletely, OCPs do not appear to be protective.

## **Gonadotropin-Releasing Hormone Agonists (GnRH-a)**

After noting that premenarchal female gonads appear to be least sensitive to cytotoxic drugs (14, 22), investigators attempted to mimic this state by using GnRH-a. Evidence from murine and rat models suggests that adjuvant treatment with GnRH-a protects the gonads (25–27).

Although there is some controversy regarding the existence of GnRH-a receptors on the human ovary, GnRH-a receptors have clearly been detected in the rat ovary. Thus, the response may not be similar across species. The protective effect of GnRH-a on primate ovaries has been investigated. Ataya et al. (28) found that GnRH-a protected the Rhesus monkey ovary from cyclophosphamide-induced damage. Six monkeys received cyclophosphamide injections. They were divided into two groups and received either leuprolide acetate or placebo injections. Sixty-four percent of the total primordial follicles were lost in the cyclophosphamide-only group versus 29% in the lupron group.

Multiple studies have failed to show a protective effect of GnRH-a on human male gonads exposed to cytotoxic drugs (29, 30). Waxman et al. (29) performed one of the first clinical studies in which GnRH-a was used to down-regulate the ovaries of eight women who were undergoing chemotherapy. At follow-up, four of eight women who had received the agonist were amenorrheic versus six of nine controls. Thus, it appeared that buserelin was not effective in preserving fertility in this population of humans. However, it is possible that complete pituitary ovarian suppression was not achieved, which may be a necessary condition for these drugs to work.

Blumenfeld and colleagues (31–33) have reported on the largest group of females exposed to both cytotoxic drugs and GnRH-a thus far. Sixty patients with lymphoma were started on GnRH-a 7–10 days before their chemotherapy regimen. The control group consisted of 60 historical patients of similar age range who were treated with chemotherapy but not GnRH-a. The rate of POF was 5% in the GnRH-a/chemotherapy group versus 55% in the chemotherapy-alone group. Recently, another preliminary report has been released regarding the use of GnRH-a for protection of the adolescent ovary during cancer treatment. All GnRH-a-treated adolescents resumed cyclic ovarian function, whereas all chemotherapy-only patients experienced hypergonadotropic hypogonadism (17).

## **Progesterone (P<sub>4</sub>)**

Using a rat model, Montz (34) found a protective effect of P<sub>4</sub> on the female gonad. Female rats were exposed to P<sub>4</sub> 1 week before the start of cyclophosphamide and during the treatment. The fertility and fecundity rates of P-exposed rats were similar to those of the control animals that had not been exposed to cyclophosphamide. A few years later, Familiari et al. (35) evaluated the ultrastructural changes in the pri-

mordial follicles of humans exposed to cytotoxic drugs and medroxyprogesterone acetate (MPA). The number of follicles noted in the chemotherapy plus MPA group was smaller than that of the control plus MPA group ( $19.37 \pm 3.41/\text{mm}$  vs.  $28.55 \pm 6.59/\text{mm}$ ).

Using electron microscopy, they found an increased frequency of cellular features that are typically seen during early atresia in both the oocytes and the accompanying follicle cells (35). These changes were seen 4–5 months after chemotherapy was completed. They concluded that chemotherapy not only acutely damaged the ovary by reducing the number of follicles, but also chronically damaged the quality of the follicles. These ultrastructural changes seem to indicate that factors produced by gonadal cells are modified by chemotherapeutic drugs, leading to a subsequent increase in rate of atresia. MPA was unable to protect the ovary from early follicular atresia.

## **Apoptotic Inhibitors**

The role of apoptosis in the process of normal germ cell depletion both prenatally and postnatally is well documented (36, 37). The existence of a genetic predetermined pathway that initiates and regulates germ cell apoptosis has raised the possibility that this pathway could be activated aberrantly by chemotherapeutic drugs (38). When mice oocytes were exposed to doxorubicin *in vitro*, they underwent a series of changes leading to the formation of apoptotic bodies (39). Because a series of specific signaling events are activated in the cell that is bound for apoptosis, inhibiting these signaling events could potentially stop the apoptotic process and protect the patient from POF.

Sphingosine-1-phosphate may be an example of an apoptotic inhibitor. Ceramide is a sphingolipid molecule that is believed to be an early messenger that signals apoptosis in response to stress. The oocytes of mice that lacked the enzyme to generate ceramide, acid sphingomyelinase, and wild-type mice oocytes that had been treated with sphingosine-1-phosphate therapy resisted apoptosis that was induced by doxorubicin (40). With the eventual identification of the molecular and genetic framework of chemotherapy-induced germ cell death, apoptotic inhibitors may some day play a role in preventing oocyte loss.

## **SURGICAL TRANSPOSITION**

The ovarian follicles are remarkably vulnerable to DNA damage from ionizing radiation. Irradiation results in ovarian atrophy and reduced follicle stores (41). On the cellular level, oocytes show rapid onset of pyknosis, chromosome condensation, disruption of the nuclear envelope, and cytoplasmic vacuolization. Serum levels of FSH and LH rise progressively and serum estradiol (E<sub>2</sub>) levels decline within 4–8 weeks after radiation exposure (42). The degree and persistence of ovarian damage and suppression of ovarian function is related to the patient's age and the dose of

TABLE 1

Effect of radiation dose and age on ovarian function.

Ovarian dose (cGy)	Results
60	No deleterious effect
150	No deleterious effect in young women; some risk for sterilization in women older than 40
250–500	In women aged 15–40, 60% permanently sterilized; remainder may suffer temporary amenorrhea. In women older than 40, 100% permanently sterilized
500–800	In women aged 15–40, 60%–70% permanently sterilized; remainder may experience temporary amenorrhea. No data available for women over 40
>800	100% permanently sterilized

Note: From Damewood and Grochow (42).

Falcone. Ovarian function preservation. *Fertil Steril* 2004.

radiation delivered to the ovaries (1, 42, 43) (Table 1). Two studies indicated that the cutoff for radiation-induced ovarian failure is around 300 cGy. Only 11%–13% experienced ovarian failure below 300 cGy versus 60%–63% above that threshold value (44). Adding chemotherapy increases the risk of POF (45, 46).

Several cancers that afflict young premenopausal women can be cured with radiation therapy. These include cervical, vaginal, and anorectal carcinomas, dysgerminoma, Hodgkin's disease, and central nervous system tumors. Because of early detection, approximately half of the patients with cervical cancer are premenopausal and about one-third are younger than 40 years of age (47). An even higher proportion of women with the other aforementioned cancers are premenopausal (43). The radiation doses used with standard pelvic radiation therapy will uniformly induce ovarian failure.

To improve quality of life and preserve fertility in these young women, ovarian function has been maintained for over three decades by transposing the ovaries out of the field of irradiation. The ovarian dose after transposition is reduced to approximately 5%–10% of that in the untransposed ovaries (48–50). The dose to each transposed ovary is 126 cGy for intracavitary radiation, 135–190 cGy for external radiation therapy (4,500 cGy), and 230–310 cGy with the addition of para-aortic node irradiation (4,500 cGy) (50).

Initially, ovarian transposition for patients with Hodgkin's disease who were receiving nodal irradiation was performed by suturing the ovaries posterior to the uterus and shielding them during treatment. Later, the ovaries were mobilized laterally out of the pelvic field. Gaetini et al. (45) reported that of the 3,600 cGy delivered to central axis with total nodal irradiation for Hodgkin's disease, the ovaries in a normal position were exposed to 3,524 cGy, whereas those

that were transposed medially received 534 cGy and those transposed laterally received 319 cGy.

Hadar et al. (51) performed computed tomography follow-up of seven patients with cervical cancer who underwent lateral ovarian transposition and nine patients with Hodgkin's disease with medial transposition before radiation therapy. Six of the seven patients with lateral transposition had ovaries outside the field, and all retained ovarian function. In that group, the radiation dose ranged from 100 to 300 cGy. The one patient with ovaries within the field received 450 cGy and developed ovarian failure. Only three of the 13 identified ovaries after medial transposition were outside the field, and those three ovaries received approximately 300 cGy (51). A compilation of 10 case reports and small series comparing medial and lateral transposition noted ovarian failure in 50% and 14% of patients, respectively (52).

Lateral ovarian transposition is typically performed by laparotomy at the time of radical hysterectomy for cervical cancer or staging laparotomy for Hodgkin's disease. The utero-ovarian ligament is divided, and the ovary is mobilized with the ovarian vessels to the paracolic gutters. Ideally, the vascular pedicles are kept retroperitoneal to avoid tension, torsion, or trauma and bowel herniation while the ovaries remain intraperitoneal to reduce cyst formation (47, 53).

Van Beurden et al. (54) reported that with a tumor dose of 4,000 cGy for cervical cancer, the ovaries receive 280 cGy at 3 cm and 200 cGy at 4 cm from the radiation field edge because of scatter. Bidzinski et al. (55) confirmed that ovarian function was preserved if they were transposed at least 3 cm from the upper border of the field. In another study, 100% of patients whose transposed ovaries were above the iliac crest maintained ovarian function versus 0 of those whose ovaries were below the crest (56). Ovarian failure may result if the ovaries are not moved far enough out of the radiation field or if they migrate back to their original position. Ovarian failure after transposition may also be due to compromised ovarian vessels from the surgical technique or radiation injury to the vascular pedicle (57).

Ovarian transposition without radiation therapy may increase the risk for ovarian failure, as may hysterectomy. Table 2 summarizes the rates of POF and mean age of menopause for several studies after radical hysterectomy for cervical cancer alone and with the addition of ovarian transposition with and without radiation therapy. Devascularization injury to the ovary may also occur during a hysterectomy for benign disease resulting in ovarian failure occurring approximately 5 years earlier than in the general population (45.4 vs. 49.5 years) (58).

Ovarian transposition is of limited value in patients who are older than 40 because they have an intrinsically reduced fertilization potential as well as a much higher risk for ovarian failure despite transposition (59).

TABLE 2

Rates of premature ovarian failure and age of menopause.

Source	Radical hysterectomy	Ovarian transposition <sup>a</sup>	Ovarian transposition and radiation therapy <sup>a</sup>
Buekers (84)	0%; menopause, 50.6 y	2%; menopause, 45.8 y	59%; menopause, 36.3 y
Anderson (47) <sup>b</sup>	13.6%; menopause, 38 y	37%; menopause, 40 y	83.3%; menopause, 33 y
Chambers (60)	4.1%	4.3%	29%
Feeney (57)		0%	50%
Morice (59)		0%	40%

<sup>a</sup> In addition to radical hysterectomy.<sup>b</sup> Performed unilateral transposition in 78% of cases.Falcone. Ovarian function preservation. *Fertil Steril* 2004.

Another concern with ovarian transposition is the development of symptomatic ovarian cysts. The mechanism that causes the cysts is unknown (60). The transposed ovaries can be followed with computed tomography and ultrasound (61, 62). Symptomatic ovarian cysts requiring reoperation develop in 1%–5.2% of patients after hysterectomy for benign disease and in 4.9%–7.6% of patients after radical hysterectomy only (57, 60).

Chambers et al. (56, 60) reported symptomatic cysts in 7.4% of patients with radical hysterectomy, in 24% of patients who also underwent ovarian transposition, and in 7% of patients who also received radiation. The lower rate after radiation therapy was likely due to the fact that 29% of those patients had ovarian failure versus 4% of those with radical hysterectomy with or without ovarian transposition (56). Similarly, Morice et al. (59) reported symptomatic cysts in 31.4% of patients after radical hysterectomy and ovarian transposition but none in patients who also received external pelvic radiation. Functional cysts in the transposed ovaries can be suppressed with oral contraceptives or GnRH-a (63).

Performing ovarian transposition routinely during radical hysterectomy for cervical cancer may further compromise ovarian function due to vascular injury and lead to symptomatic cyst formation. Radiation therapy is indicated in only 15%–37% of patients with stage 1–2 disease with positive margins, stromal invasion, parametrial extension, vascular and/or lymphatic space invasion, or positive lymph nodes (54, 56, 57). Radiation therapy is usually administered several months after ovarian transposition by laparotomy to allow the incision to heal. However, during that time, the ovaries can migrate back to their original position, accounting for many cases of ovarian failure (46). Treisman et al. (64) estimated that 39% of transposed ovaries may revert to their original position in the radiation field, but it was not stated how they calculated that figure.

For the above reasons, ovarian transposition should be performed laparoscopically just before the start of radiation therapy. This will eliminate unnecessary transposition in most cervical cancer cases where radiation therapy is not

required. An important advantage of laparoscopic ovarian transposition is that radiation therapy can be initiated immediately after surgery, thereby avoiding ovarian migration and failure (46, 64, 65). When vaginal or cervical cancers are treated with brachytherapy, laparoscopic ovarian transposition can be performed under the same anesthetic (43).

Staging laparotomy and splenectomy are no longer required for stage 1 and 2 Hodgkin's disease (46). This eliminates the need for laparotomy because ovarian transposition can be performed laparoscopically as an outpatient procedure, which is associated with a more rapid recovery, less discomfort, better cosmesis, and lower cost. Nearly all women with stage 1 and 2 Hodgkin's disease who are treated with radiation alone or with minimal chemotherapy after laparoscopic ovarian transposition retain their ovarian function and fertility (46). Morice et al. (66) reported that ovarian function was preserved in 79% of patients after laparoscopic ovarian transposition and radiation therapy for various indications.

Ovarian preservation did not increase the risk of occult ovarian metastasis in patients with stage 1B cervical carcinoma without gross extracervical disease (67). Another study found no significant difference in the 5-year survival rates in cervical cancer patients with and without retained ovaries (68).

However, patients with tumors that are more than 3 cm in diameter are at a high risk for metastasis to the ovaries and are not candidates for ovarian transposition (59). The rate of ovarian metastases was not correlated with histological type (67, 59). Ovarian metastases occurred in 0.5% of patients with stage 1B squamous cell cervical carcinoma and in 1.7% of patients with adenosquamous carcinoma (67). For comparison, the risk of ovarian cancer after hysterectomy for benign disease is 0.2% (69). In addition to the very low rate of ovarian metastasis with early-stage cervical carcinoma, there is a concern of inducing ovarian cancer by radiation exposure. No excess cases of ovarian cancer were observed in 2,068 women who received 500–1,000 cGy to the ovaries

for treatment of menorrhagia and who were followed up for a mean of 19 years (70).

The transposed ovaries produce  $E_2$  and  $P_4$  at pretreatment levels (71). The endometrium has been shown to function in some cases after brachytherapy and external radiation, although the effect of radiation on the endometrium was not clearly defined (72, 73). Critchley et al. (74) studied 10 patients with ovarian failure after whole abdominal radiation. The uterine length was significantly reduced; most had no uterine blood flow detectable by Doppler ultrasound, and 30% showed no endometrial response to hormone therapy. The radiation effect on the uterus was unpredictable, but higher doses were more likely to be associated with vascular and uterine damage.

Term pregnancies have been reported after intracavitary radiation for cervical cancer (50). Morice et al. (75) noted a 15% pregnancy rate after brachytherapy with or without external radiation for vaginal clear cell carcinoma versus 80% for those treated with external radiation only for dysgerminomas and pelvic sarcomas. The much lower rates seen with vaginal clear cell carcinoma were attributed to diethylstilbestrol-associated genital malformations and possibly to the effects of brachytherapy on the endometrium. Interestingly, 89% of the pregnancies were spontaneous, with 75% occurring without ovary repositioning. The ovaries were only repositioned in cases of infertility, and 11% of those patients conceived with IVF (66).

Tulandi and Al-Took (76) reported a case of laparoscopic lateral ovarian transposition in a patient with rectal adenocarcinoma whereby the utero-ovarian ligaments were divided but the ovaries remained attached to the distal fallopian tubes, which potentially improved the chances for ovum pickup. The patient achieved a spontaneous pregnancy (77).

Several papers address the concerns regarding pregnancy outcomes after pelvic irradiation. No excess cases of stillbirths, major congenital malformations, chromosomal abnormalities, or mutations were observed in 31,150 atomic bomb survivors. In addition, there was no increase in fetal wastage or birth defects in women treated for Hodgkin's disease (50). Swerdlow et al. (78) confirmed that there were no excess cases of stillbirths, low birth weight, congenital malformations, abnormal karyotypes, or cancer in the offspring of women treated for Hodgkin's disease. However, Fenig et al. (79) cited an increase in low birth weight and spontaneous abortions, especially if conception occurred less than a year after radiation exposure. They advised delaying pregnancy for a year after completing radiation therapy.

The literature contains only one case report of superovulation and oocyte retrieval for IVF with transposed ovaries that were not repositioned. In that case, a patient with cervical cancer underwent laparoscopic lymph node dissection, unilateral ovarian transposition, and chemotherapy followed by brachytherapy and external radiation before radical hys-

terectomy. Transabdominal ultrasound-guided needle aspiration after superovulation with gonadotropins yielded five oocytes. The resulting embryos were transferred to a gestational carrier who delivered normal live-born twins.

It was noted that oocyte retrieval was possibly due to the superficial location and lack of mobility of the ovary (80). To facilitate oocyte retrieval as well as the diagnosis and treatment of ovarian cysts, the ovaries have been transposed subcutaneously. This has the disadvantages of requiring a laparotomy and an additional abdominal incision and may also be associated with a higher rate of cyst formation. Transient ovulatory pain was reported by 81.5% of the patients, and 15.4% required needle aspiration (81). IVF with donor oocytes has also been reported in six women with ovarian failure after treatment for Hodgkin's disease. Pregnancy and implantation rates per cycle were 37% and 17%, respectively (82).

Lastly, it should be mentioned that medical treatment to maintain ovarian function before irradiation has also been attempted. Ataya et al. (83) found no protective effect of the GnRH-a leuprolide acetate against radiation-induced ovarian injury in Rhesus monkeys. Morita et al. (40) demonstrated that the sphingomyelin pathway regulates oocyte apoptosis. Further, *in vivo* treatment with sphingosine-1-phosphate completely prevented radiation-induced oocyte loss and preserved fertility in mice. Although the mechanism remains to be elucidated, this new approach is promising.

## **CRYOPRESERVATION OF OOCYTES, EMBRYOS, AND OVARIAN TISSUE**

The effect of very low temperatures on survival of gonadal cells and tissues is an area of extensive research in reproductive biology. The ability to preserve oocytes and ovarian tissues in a healthy state for a variable duration gives the patient who will undergo cancer treatment another option to preserve her fertility.

Cryopreservation of spermatozoa and preimplantation embryos is currently an integral part of patient care in clinical practice. Cryopreservation of oocytes and gonadal tissues (i.e., ovarian and testicular tissue) is a rapidly evolving area in reproductive medicine. Successful fertilization and embryonic cleavage have been reported after injection of cryopreserved thawed oocytes (85–88). However, the pregnancy rate is not high enough to justify its routine use in clinical practice (86, 89–91). All successful pregnancies and live births resulted from cryopreservation of mature oocytes. However, a few centers have succeeded in achieving pregnancies from cryopreserved-thawed immature (germinal vesicle) oocytes (92).

Ovarian tissue cryopreservation and transplantation techniques have a great potential for use in safeguarding the reproductive potential of endangered species and in genome banking of genetically important laboratory animal strains

(93). Moreover, ovarian tissue banking in humans is also being considered in the hope of restoring fertility to patients who lose ovarian function because of chemo- or radiotherapy during cancer treatment (94–96). However, no pregnancies have been reported in humans from the use of cryopreserved ovarian tissue.

## Oocyte Cryopreservation

The main factor that may influence the outcome in oocyte cryopreservation is its structural complexity. Oocyte subcellular organelles are far more complex and perhaps more sensitive to thermal injury than preimplantation embryos (97, 98). An ideal oocyte cryopreservation protocol should appreciate the essential role of cytoskeletal elements as well as plasma membrane functions in subsequent development (99). Several factors have been determined to be important for developing optimal cryopreservation protocols for oocytes.

### *Factors Affecting the Cryosurvival of Oocytes*

*Cryoprotective Agents.* Different osmotic pressures between the intracellular and extracellular solutions during the cryopreservation procedure lead to volume changes in the oocytes (100) with subsequent damage to the plasma membrane and subcellular organelles (101). Cryoprotectants are introduced to minimize this damage. Despite the protective effects of cryoprotective agents (CPAs) during freezing, they may lead to concentration-, time-, and temperature-dependent toxicity (102). Consequently, investigating the choice of CPA, exposure time, and temperature before freezing is necessary to optimize a cryopreservation procedure. Dimethyl sulphoxide (DMSO) was the first cryoprotectant used to cryopreserve oocytes. Chen (103) reported the first human live birth from a cryopreserved-thawed oocyte using DMSO as a cryoprotectant.

Chen's results (103) were reproduced by a few other centers including the report of two pregnancies that failed to survive to term (85). The same group shifted to the use of 1,2-propanediol (PrOH) as a cryoprotectant for human oocytes (85). The main biophysical barrier jeopardizing the cryosurvival of oocytes is intracellular ice formation with subsequent rupture of the cell membrane leading to cell lysis. PrOH exerts its cryoprotective effect by acting as a membrane-permeating cryoprotectant. When comparing the results of using DMSO and PrOH as cryoprotectants, better survival was reported with PrOH (104).

Using the same technique, Porcu (105) reported 16 pregnancies that resulted in 11 live births from cryopreservation of 1,796 oocytes. These results showed that despite early disappointing results regarding survival and fertilization and cleavage rates, the recent introduction of a technical modification may improve the clinical efficacy of this technology. It has been suggested by Porcu (105) and others that the

routine use of intracytoplasmic sperm injection (ICSI) to achieve fertilization with cryopreserved oocytes has contributed significantly to the increased success reported in her studies.

Fabbri and associates (106) evaluated the use of sucrose as a cryoprotectant for human oocytes. Sucrose acts as a non-membrane-permeating cryoprotectant. They evaluated the effect of the presence or absence of the cumulus oophorus, the sucrose concentration in the freezing solution, and the exposure time to cryoprotectants on human oocyte survival after thawing. The oocytes were cryopreserved in 1,2-propanediol with sucrose added, using a slow-freezing/rapid-thawing protocol. The post-thaw cryosurvival rate of oocytes cryopreserved with their cumuli partially removed mechanically was 56%, compared with 53% for those cryopreserved with their cumuli totally removed enzymatically. The survival rate was 60% when a sucrose concentration of 0.2 mol/L was used versus 82% when a sucrose concentration of 0.3 mol/L was used. Furthermore, lengthening the exposure time (from 10.5 to 15 minutes) to the cryoprotectants before lowering the temperature significantly increased the oocyte survival rate (106).

*Slow Freezing Versus Vitrification.* To date, slow freezing and rapid thawing is the protocol of choice for human oocytes. Vitrification was described in the late 1990s. Vitrification is based on using high concentrations of cryoprotectants to solidify the cell in a glass state without ice formation (107). Using vitrification, oocytes treated with 5.5 methyl glycol and 1 M sucrose resulted in a single pregnancy (108). However, higher concentrations of cryoprotectants may be associated with high levels of toxicity to the oocytes and developing embryos.

*Stage of Development.* Despite the resounding success of mature mouse oocyte cryopreservation (109), these results could not be duplicated in the human scenarios with the same success profile. One alternative to nullify the damaging effects of the freezing trauma on metaphase II (MII) oocytes is to cryopreserve earlier stages before resumption of full maturation. The relatively inactive metabolism, absence of zona pellucida, and lack of meiotic spindle make the cryopreservation insult the lowest at the primordial follicle levels (110). On the other hand, antral follicles contain oocytes either in the prophase I or MII stage, and their oocytes are much more susceptible to cryodamage (111). Both prophase I and MII stages have zona pellucida, but MII oocytes have a larger cell size, which makes cryoinjury more pronounced in MII oocytes. Moreover, the meiotic spindle, a unique feature of MII oocytes, is of particular importance as variations in the temperature may lead to its permanent damage (87).

Few pregnancies have been achieved using frozen-thawed germinal vesicles oocytes (112–114). In a study to evaluate the cryopreservation of immature human oocytes obtained

TABLE 3

## Mechanisms of cryodamage.

1. Meiotic spindle damage and chromosomal aberrations
2. Cytoskeleton: microtubules and microfilaments
3. Reduced number and morphological alterations of the cortical granules
4. Zona hardening resulting in failed fertilization and hatching
5. Organelle damage
6. Osmotic damage of the plasma membrane

Falcone. Ovarian function preservation. *Fertil Steril* 2004.

from unstimulated ovarian tissue, immature prophase I oocytes were obtained from unstimulated follicles and were either cryopreserved or cultured as controls. Rates of cryosurvival and maturation to MII were compared between control oocytes and cryopreserved oocytes with two different methods. Cryosurvival and maturation rates were lower in the cryopreserved-thawed immature oocytes than in the control oocytes (115).

#### ***Deleterious Effects of Cryopreservation on Oocyte Structure***

The fair success of cryopreservation is partially attributed to the cryoinjury. A wide spectrum of subcellular damages may occur as a consequence of the freeze-thaw trauma (Table 3). These include meiotic spindle damage that may lead to chromosomal instability. Other injuries include destruction of the microtubules, which are an essential component for polar body extrusion, pronuclear migration, and cytokinesis. Furthermore, aneuploid embryos have been obtained from oocytes exposed to 1.5 M DMSO without cooling, which suggests CPA-induced DNA damage (116). Other reported abnormalities from cryopreservation of oocytes include hardening of zona pellucida by alteration of its glycoproteins, particularly ZP2, which might lead to failure of hatching and implantation (104, 117), and abnormalities in cortical granules causing a premature cortical reaction. Better choice of CPA, efficient instrumentation, and refinement of the available cryopreservation protocol could minimize or even prevent cryoinjury.

#### ***Potential Use of Oocyte Cryopreservation for Ovarian Function Protection***

An increasing number of pregnancies and live births have been reported after oocyte cryopreservation and subsequent intracytoplasmic sperm injection (ICSI) (86, 103). Oocyte cryopreservation is currently used electively in patients with ovarian hyperstimulation syndrome to avoid the ethical implications of embryonic cryopreservation. Given the improved cryosurvival, fertilization, pregnancy, and birth rates, oocyte cryopreservation can be used in cancer patients as a fertility preservation procedure.

## **Cryopreservation of the Preimplantation Human Embryo for Ovarian Function Protection**

Embryo cryopreservation was introduced to maximize the conception chances from a single cycle. The Society of Assisted Reproductive Technology has reported delivery rates per embryo transfer (ET) using cryopreserved embryos (118) to be 18.6%. This option may not be acceptable to prepubertal girls, adolescents, and women without a partner. However, acceptable, long-term data are available about the outcome of children born from these procedures. Typically, a standard IVF protocol is used. Because of time constraints, this is usually a short-flare protocol (119).

However, there is some concern that in patients with breast cancer, the high estrogen levels obtained in a standard IVF cycle may negatively affect long-term survival. For this reason, some centers have offered natural-cycle IVF—oocyte aspiration in an unstimulated cycle. However, cancellation rates are high and the pregnancy rates are very low (7.2% per cycle and 15.8% per ET) (120).

Recently, the use of tamoxifen—a nonsteroidal anti-estrogen—has been investigated for ovarian stimulation for IVF (121). Tamoxifen (40–60 mg) was started on day 2 or 3 of the cycle and given daily for 5–12 days. If a GnRH-antagonist was required, a low-dose gonadotropin was also given until follicular maturity. Embryos were frozen at the pronuclear stage. The tamoxifen group had a mean of 1.6 embryos versus 0.6 embryos for the natural cycle group. The peak E<sub>2</sub> concentration in the tamoxifen group was higher than the natural-cycle group. Some researchers are investigating the use of aromatase inhibitors for use in these patients. These inhibitors are associated with much lower E<sub>2</sub> levels that may be critical for estrogen sensitive tumors.

## **OVARIAN TISSUE CRYOPRESERVATION AND TRANSPLANTATION**

Ovarian cryopreservation and transplantation is an experimental procedure that was introduced to preserve fertility in women with threatened reproductive potential (96). Studies investigating the effects of cryopreservation insult on ovarian tissues have been limited compared with those studying the same effects on oocytes (122). Unlike a suspended single cell, tissue cryopreservation presents serious physical constraints related to heat and mass transfer. Furthermore, because it is a multicellular structure for which cell-to-cell interactions are known to exist, the dynamics of cryoprotectant permeation into and out of the tissue during cryopreservation are of utmost importance for subsequent tissue survival. Under the effect of the hypertonic cryoprotectants, water will be osmotically drawn from the individual cells to the extracellular spaces and blood vessels. It is this water that is responsible for the formation of ice crystals, which is responsible for the freeze-thaw injury (123). Consequently,

better survival is expected from primordial follicles because of their smaller size and lack of follicular fluid.

As in other reproductive technologies, animal models have provided useful information in transferring methods to treat human infertility. With the sheep ovary providing a reliable tool, Gosden and associates pioneered the sheep ovarian transplantation model. Using cryopreserved-thawed ovarian cortical strips, they showed follicular survival and endocrine function as well as restoration of fertility after transplantation of cryopreserved-thawed ovarian cortical strips (124, 125). The success achieved in orthotopic transplantation of cryopreserved ovarian tissue from both mouse and sheep resulted in the subsequent use of this technique in human reproductive medicine.

There are several potential uses of cryopreserved ovarian tissue. The tissue can be transplanted back into the patient. The potential for reintroduction of a cancer nidus may limit this use in malignancies that are known to have a predilection for the ovaries. Using present techniques, ischemic injury to the transplanted tissue results in the loss of virtually the entire growing follicle population and a significant number of primordial follicles. This could limit its long-term viability.

Alternatively, the primordial follicles in the ovarian tissue can be matured *in vitro* or in an immune-deficient animal host. The former cannot be accomplished with present technology, and the latter is unlikely to be acceptable to patients.

### **Factors Affecting the Outcome of Ovarian Tissue Cryopreservation and Transplantation**

#### **CPAs**

Looking into follicular loss after exposure of human ovarian tissue to different cryoprotectants, Newton et al. demonstrated that human ovarian tissue lost 90% of the primordial follicle population when using glycerol as a CPA compared with 25%, 15%, and 55% using DMSO, ethylene glycol (EG), and propylene glycol (PG), respectively, after transplantation in severe combined immunodeficient (SCID) mice. This was the first xenografting study in which 1- to 2-mm ovarian cortical strips were grafted in SCID mice (126). Glycerol had such a hazardous effect because of its low permeability coefficient compared with DMSO and EG or PG.

The same observation was confirmed by a later work of Candy et al. (127), who compared the effects of four different CPAs on the survival of mouse ovaries after exposure to 1.5 M DMSO, PG, EG, or glycerol for 5–60 minutes at room temperature before freezing. More primordial follicles survived when the ovaries were frozen in DMSO, PG, and EG (81%–94%) than in glycerol (4%–28%). Furthermore, it was found that prolonged exposure to EG decreased the survival rate, whereas increasing the exposure to glycerol increased the survival rate. Overall, the total number of follicles re-

maining in the ovary grafts frozen in DMSO and PG represented 42%–46% of follicles present in nongrafted ovaries, which was not significantly different from grafts of fresh ovaries (63%).

To achieve optimal cryoprotection, it is essential that freezing protocols allow uniform penetration of CPAs throughout the ovarian tissue. Candy et al. (127) concluded that the rate of CPA permeation is an important limiting factor in developing better cryopreservation protocols for ovarian tissues.

Looking into the effect of the diffusion temperature, Newton et al. (128) have investigated the DMSO, PG, EG, and glycerol diffusion into human ovarian tissue at both 4°C and 37°C. They found that at 4°C, PG and glycerol penetrate the tissue significantly more slowly than either EG or DMSO. At the higher temperature (37°C), however, all four CPAs penetrated at a faster rate.

Tissue penetration of cryoprotectant in whole organ systems is even more challenging. The transplant literature, such as with kidneys, reports several protocols that strive to protect the tissue before transplantation. These protocols try to perfuse the whole organ with a “protecting” agent. The potential for cryopreserving the entire ovary has the same methodological limitations. The cryoprotectant can be perfused through the ovarian vessels using a special pump to achieve the appropriate tissue penetration. Using this cryopreservation model, pregnancies in rats (129) and partial restoration of hormonal function in sheep were recently reported (130).

#### ***Effect of Ischemia***

Cryopreservation of small (1–2 mm) ovarian cortical strips has been used for efficient cryoprotection because the rate of CPA/cellular water exchange is affected by the amount of tissue through which the CPA must diffuse. During the cooling stage of cryopreservation, the relative distance of cells in the interior of the ovary from the exterior affects the rate at which these cells undergo cooling.

These tissue strips are placed back into the body without a vascular supply. Consequently, the ability of cells in the graft to obtain nutrients from their surroundings before permanent revascularization depends on the diffusion of those nutrients through the surrounding tissue. However, studies with fresh transplants suggest that 50% of the follicular population is damaged after transplantation in mice (131) and 26% in human studies (126).

In the latter study, ovarian cortical strips donated by healthy patients were cryopreserved for 2 months in DMSO, EG, glycerol, and propylene glycol. Their viability was assessed by counting follicles in histological sections 18 days after grafting under the kidney capsules of SCID mice, and the results were expressed as percentages of the numbers in comparable pieces of ungrafted tissue. Only 10% of the

total number of follicles were found in the glycerol group compared with the controls, whereas significantly higher percentages (44%–84%) survived cryopreservation in the other media. These results confirm that substantial numbers of follicles are lost during graft establishment.

Ischemia is a critical factor in follicular loss and can potentially occur at different steps: during the stages of preparation of tissue for cryopreservation, during the stages of preparation for transplantation, and during the revascularization process after transplantation. We conducted a study in which the harvested ovaries of a porcine animal model were divided into five segments and subjected to assigned time intervals in warm ischemia (1, 5, 10, 20, and 30 minutes) before cryopreservation (132). The ovarian strips were prepared for cryopreservation using two different sizes: 1–2 mm (C-s) and 5 mm (C-l). The cryopreserved tissue was then thawed and compared with the noncryopreserved tissue controls (F). We found that the number of primordial follicles per high magnification field was significantly reduced in the cryopreserved group (C:  $4.9 \pm 5.3$  vs. F:  $7.2 \pm 5.4$ ;  $P=.03$ ). However, stratifying the cryopreserved group according to size showed a significantly higher follicle count for larger tissue sections (C-l:  $9.3 \pm 6.5$  vs. C-s:  $2.1 \pm 2.4$ ;  $P=.002$ ). The number of primordial follicles was not significantly changed when comparing cryopreserved tissue segments measuring 5 mm to noncryopreserved sections (C-l:  $9.3 \pm 6.5$  vs. F:  $7.2 \pm 5.4$ ; NS). The processing time of up to 30 minutes before cryopreservation did not appear to have a significant impact on primordial follicle survival (132).

### Vascularized Versus Nonvascularized Grafts

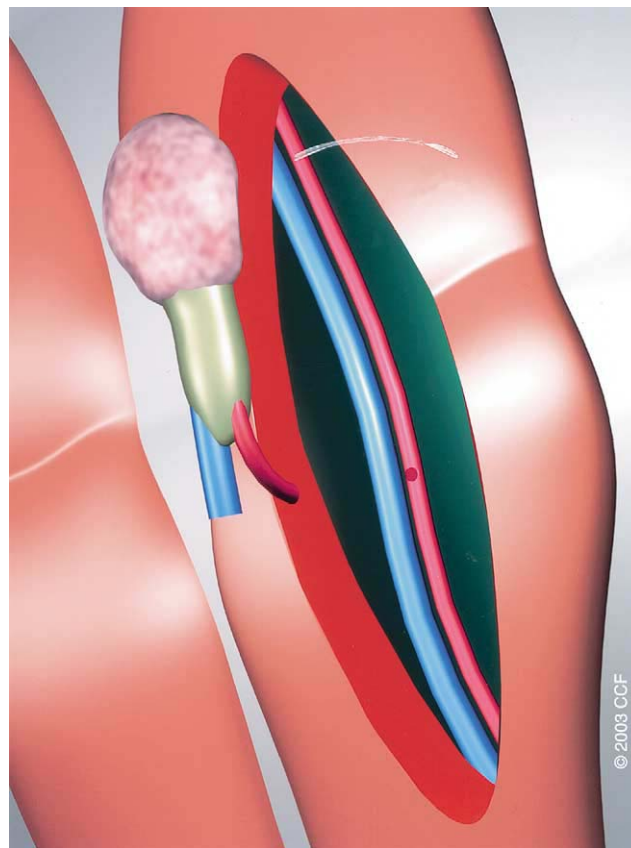
Revascularization ischemia is a major limiting factor that has been shown to affect primordial follicle survival in the transplanted graft. In an attempt to minimize follicular loss and maintain the function of the ovarian grafts, transplantation of intact ovary with microvascular anastomosis has been attempted in an animal model. If successful, this would guarantee immediate vascularization and minimize post-transplantation ischemia time.

Although whole ovaries from mice and rats survive freezing because of their smaller sizes, successful cryopreservation of whole ovaries from other mammalian species such as human and nonhuman primates is more technically challenging because of heat and mass transfer limitations as well as post-transplantation limitations. Typically, the human ovary is  $4 \times 2 \times 0.8$  cm in size and weighs between 20 and 35 grams, whereas the sheep ovary is  $2.5 \times 1.5 \times 0.5$  cm in size and weighs between 3 and 8 grams.

We conducted a study in which we transplanted an entire ovary and anastomosed the ovarian vascular pedicle to the deep inferior epigastric artery. Laparoscopic bilateral oophorectomy was performed in five adult, nonpregnant ewes. Six ovaries were autotransplanted into the abdominal wall and microsurgical vascular anastomosis of the ovarian to the

FIGURE 1

Autotransplantation of intact ovary with its vascular pedicle to the deep inferior epigastric artery.



Falcone. Ovarian function preservation. *Fertil Steril* 2004.

inferior epigastric vessels was performed (Fig. 1). The transplant was removed and evaluated after  $7 \pm 1$  days. Blood flow was observed for at least 20 minutes in all transplants. At follow-up, three transplants were viable, without any signs of necrosis, with patency of the vascular anastomosis confirmed. In two cases, the vessels occluded completely. In one case, a venous thrombosis led to major tissue injury.

There was no significant change in serum  $E_2$  levels before and after transplantation in either the patent vessel group ( $155.3 \pm 46.1$  vs.  $125.7 \pm 44.6$  pg/mL) or the nonpatent vessel group (99 vs. 158 pg/mL). Serum FSH in the patent vessel group did not change significantly from pre- to post-transplantation ( $70.6 \pm 37.2$  vs.  $95.1 \pm 17.7$  ng/mL;  $P=.22$ ), whereas a steep rise in FSH was observed in the nonpatent vessel group ( $52.3$  vs.  $522$  ng/mL). There were significantly more follicles present in the patent than in the nonpatent vessel group after transplantation ( $6 \pm 1$  vs.  $1 \pm 1$ ;  $P=.004$ ), which correlated well with the histological examination of preserved tissue in the patent vessel group. Transplants in the nonpatent vessel group, however, showed severe necrosis

with focal viable tissue. This experiment proved the feasibility of using vascularized fresh ovarian grafts (133).

In another experiment, we tested the feasibility of transplanting intact frozen-thawed ovary with microvascular anastomosis of the ovarian vascular pedicle to the deep inferior epigastric vessels using the same technique. Bilateral laparoscopic oophorectomy was performed in 17 adult, synchronized merino ewes. In one group of animals (group 1,  $n = 11$ ), both ovaries were cryopreserved intact with their vascular pedicle. In another group of animals (group 2,  $n = 6$ ), ovarian cortical strips were prepared from each ovary and cryopreserved. After thawing, follicular viability and apoptosis rates were assessed using one ovary. The other ovary was transplanted to the abdominal wall with microvascular anastomosis to the deep inferior epigastric vessels (group 1). In group 2, the ovarian cortical strips were placed in the anterior abdominal wall. Ovaries were harvested after 10 days in situ and subjected to histological evaluation.

Our outcome measures were blood flow, apoptotic signals, follicular viability, serum  $E_2$ , FSH, and histology. There were no significant differences in the mean values of apoptosis and follicular viability in both groups. In group 1, immediate and long-term patencies were documented in 100% (11/11) and 27% (3/11) of the grafts, respectively. Postoperative FSH levels were similar to preoperative values in animals with patent vessels. In group 2, postoperative FSH levels were significantly higher than the preoperative levels ( $P=.03$ ). From this study, we concluded that transplantation of intact frozen-thawed ovary is technically feasible. Using this approach, it would be possible to immediately restore the vascular supply and ovarian hormonal function (130). Research is now required to demonstrate its application in humans.

### **Potential Utility of Cryopreserved Ovarian Tissue: Xenografting of Human Ovarian Tissue**

Transplantation studies performed in SCID mice have provided extremely important information that is useful in understanding many technical and laboratory aspects of ovarian tissue banking. An important finding was the demonstration of improved follicle growth upon administration of exogenous FSH to the recipient mice. Oktay et al. (134) xenografted human ovarian tissue under the kidney capsules of hypogonadal SCID mice to study the early stages of ovarian follicular growth in vivo. In the absence of FSH, after 17 weeks of grafting, the most advanced follicles contained two layers of granulosa cells. Follicular growth up to the antral stage was significantly improved by employing a daily injection of 1 IU of FSH.

In another study, the same group grafted human ovarian cortical strips under the kidney capsule of eugonadal SCID mice without subsequent administration of FSH. Twenty-two weeks later, the grafts were recovered and histopatho-

logical examination showed that significant numbers of the follicles had initiated growth (135). Weissman and associates (136) attempted to evaluate the development of follicles in human ovarian cortex grafted under the skin of nonobese diabetic SCID mice. Exogenous gonadotropin administration 12 weeks after transplantation resulted in follicle growth in 51% of the grafts.

### **Autografting of Human Ovarian Tissue**

Oktay and his associates (137, 139) developed two different surgical techniques of ovarian cortical strip transplantation. In their first experimental surgery, they placed ovarian cortical strips beneath the pelvic peritoneum of the ovarian fossa laparoscopically. The patient was 17 years old when right salpingo-oophorectomy was performed for dermoid cyst and was 28 years old when left salpingo-oophorectomy with subsequent cryopreservation of the cortex was performed as a treatment for intractable menometrorrhagia. The transplantation was performed at the age of 29, when partial viability of the cortical strips was proven by in vitro studies. The cortical strips were threaded and anchored to an absorbable cellulose membrane followed by transplantation to the selected site. The graft established its blood supply as early as 3 weeks postoperatively as evidenced by Doppler ultrasound scanning. After 24 days of gonadotropin stimulation, they were able to document ovulation based on hormonal and ultrasound features followed by menstruation 16 days after the first hCG injection (137). Long-term follow-up of this case has not been published.

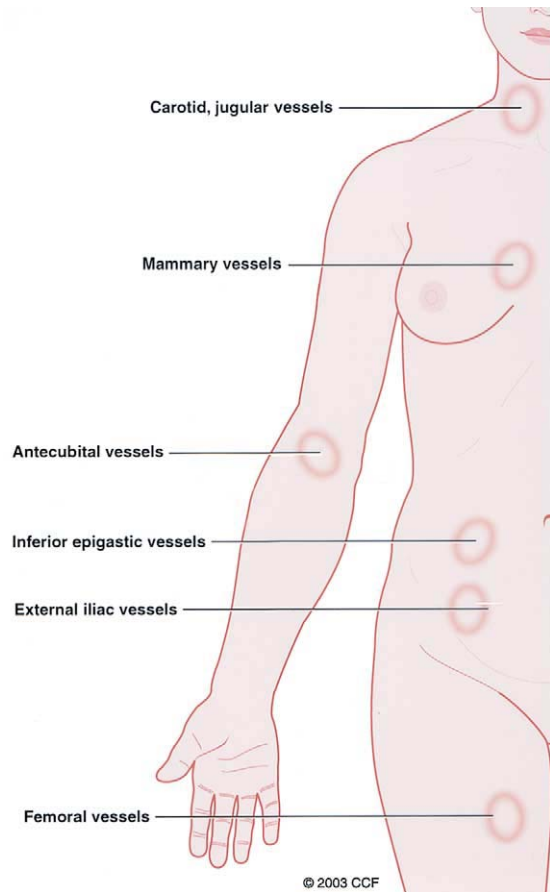
Another case of orthotopic transplantation of ovarian cortical strips was reported in a 32-year-old woman with stage 3B Hodgkin's lymphoma after high-dose chemotherapy (138). Seven months after transplantation, she obtained menopausal symptomatic relief, and her  $E_2$  level rose to 100 pg/mL with a 2-cm follicle at the transplantation site. The graft completely ceased functioning 9 months after transplantation. The fact that the patient received many chemotherapy cycles before cryopreservation may in part be responsible for the early failure of the graft.

In their second experimental surgery, Oktay and his group (139) used the forearm as the transplant recipient site in two patients. The first patient was a 35-year-old woman with stage 3B squamous cell carcinoma. Fresh ovarian cortical strips were grafted over the fascia of the brachioradialis muscle. A 15-mm follicle was detected by ultrasound 10 weeks after the procedure. Several oocytes were retrieved percutaneously after gonadotropin stimulation. ICSI was tried in a single oocyte, but fertilization did not occur. The FSH level was normal at 18-month follow-up.

The second patient was a 37-year-old woman who underwent oophorectomy for recurrent ovarian cysts. Heterotopic transplantation with fresh ovarian cortical strips was performed in a fashion that was similar to that performed in the first patient. The patient resumed her regular menses and

**FIGURE 2**

Potential recipient sites for vascularized and nonvascularized ovarian grafts.



Falcone. Ovarian function preservation. *Fertil Steril* 2004.

ovulated 3 months later. Her graft was still functioning 10 months after the transplant (139).

In a final study by Callejo et al. (140), these authors evaluated the long-term function of both fresh (three patients) and cryopreserved (one patient) ovarian autografts in four premenopausal patients age 46–49 years who underwent heterotopic ovarian transplantation. Although ovarian function was reestablished in three patients, a 2- to 7-fold increase in FSH levels was reported. One patient did not recover ovarian function. This study's main limitation was the age of the women.

It is critical for patients to understand that no pregnancies have been reported in humans with these techniques. Research should focus on refining cryopreservation protocols, cryoprotectants, and transplantation techniques that decrease ischemia. When selecting a transplantation site, physicians should consider whether it can be accessed using simple and minimally invasive surgery. Moreover, ample blood supply

to the recipient site is important for graft establishment, survival, and long-term function. Subsequent manipulations of the grafted ovary as in follicle aspiration should be made simple. For all these reasons collectively, we are providing a hypothetical model for the potential recipient sites (Fig. 2A and 2B).

## CONCLUSION

There are many options that are available to a patient undergoing a treatment that will negatively impact her fertility. This review has focused on the potential success and limitations of these techniques. Many procedures and medical interventions have proven success rates both in terms of ovarian function and pregnancy rates. Other techniques have great potential but do not have long-term clinical data. It is important that the patient's primary care physician understand the available methods to preserve fertility in cancer patients and communicate this information to the patient.

## References

1. Meirou D, Nugent D. The effects of radiotherapy and chemotherapy on female reproduction. *Hum Reprod Update* 2001;7:535–43.
2. Chapman RM. Effect of cytotoxic therapy on sexuality and gonadal function. *Semin Oncol* 1982;9:84–94.
3. Rivkees SA, Crawford JD. The relationship of gonadal activity and chemotherapy-induced gonadal damage. *JAMA* 1988;259:2123–5.
4. Warne GL, Fairley KF, Hobbs JB, Martin FI. Cyclophosphamide-induced ovarian failure. *N Engl J Med* 1973;289:1159–62.
5. Bines J, Oleske DM, Cobleigh MA. Ovarian function in premenopausal women treated with adjuvant chemotherapy for breast cancer. *J Clin Oncol* 1996;14:1718–29.
6. Shamberger RC, Rosenberg SA, Seipp CA, Sherins RJ. Effects of high-dose methotrexate and vincristine on ovarian and testicular functions in patients undergoing postoperative adjuvant treatment of osteosarcoma. *Cancer Treat Rep* 1981;65:739–46.
7. Gradishar WJ, Schilsky RL. Ovarian function following radiation and chemotherapy for cancer. *Semin Oncol* 1989;16:425–36.
8. Plowchalk DR, Mattison DR. Phosphoramide mustard is responsible for the ovarian toxicity of cyclophosphamide. *Toxicol Appl Pharmacol* 1991;107:472–81.
9. Jarrell J, Lai EV, Barr R, McMahon A, Belbeck L, O'Connell G. Ovarian toxicity of cyclophosphamide alone and in combination with ovarian irradiation in the rat. *Cancer Res* 1987;47:2340–3.
10. Sobrinho LG, Levine RA, DeConti RC. Amenorrhea in patients with Hodgkin's disease treated with antineoplastic agents. *Am J Obstet Gynecol* 1971;109:135–9.
11. Blumenfeld Z, Avivi I, Ritter M, Rowe JM. Preservation of fertility and ovarian function and minimizing chemotherapy-induced gonadotoxicity in young women. *J Soc Gynecol Invest* 1999;6:229–39.
12. Goldhirsch A, Gelber RD, Castiglione M. The magnitude of endocrine effects of adjuvant chemotherapy for premenopausal breast cancer patients. The International Breast Cancer Study Group. *Ann Oncol* 1990;1:183–8.
13. Koyama H, Wada T, Nishizawa Y, Iwanaga T, Aoki Y. Cyclophosphamide-induced ovarian failure and its therapeutic significance in patients with breast cancer. *Cancer* 1977;39:1403–9.
14. Chiarelli AM, Marrett LD, Darlington G. Early menopause and infertility in females after treatment for childhood cancer diagnosed in 1964–1988 in Ontario, Canada. *Am J Epidemiol* 1999;150:245–54.
15. Watson AR, Taylor J, Rance CP, Bain J. Gonadal function in women treated with cyclophosphamide for childhood nephrotic syndrome: a long term follow-up study. *Fertil Steril* 1986;46:331–7.
16. Nicosia SV, Matus-Ridley M, Meadows AT. Gonadal effects of cancer therapy in girls. *Cancer* 1985;55:2364–72.
17. Pereyra Pacheco B, Mendez Ribas JM, Milone G, Fernandez I, Kvicala R, Mila T, et al. Use of GnRH analogs for functional protection of the ovary and preservation of fertility during cancer treatment in adolescents: a preliminary report. *Gynecol Oncol* 2001;81:391–7.
18. Ortin TT, Shostak CA, Donaldson SS. Gonadal status and reproductive function following treatment for Hodgkin's disease in childhood: the Stanford experience. *Int J Radiat Oncol Biol Phys* 1990;19:873–80.

19. Bakchine H, Brauner R, Thibaud E, Rappaport R, Flamant F, Griscelli C, et al. Chemotherapy and ovarian function. Retrospective analysis in 17 girls treated for malignant tumor or hematologic disease. *Arch Fr Pediatr* 1986;43:611–6.
20. Wallace WH, Shalet SM, Tetlow LJ, Morris-Jones PH. Ovarian function following the treatment of childhood acute lymphoblastic leukaemia. *Med Pediatr Oncol* 1993;21:333–9.
21. Green DM, Zevon MA, Lowrie G, Seigelstein N, Hall B. Congenital anomalies in children of patients who received chemotherapy for cancer in childhood and adolescence. *N Engl J Med* 1991;325:141–6.
22. Tangir J, Zelterman D, Ma W, Schwartz PE. Reproductive function after conservative surgery and chemotherapy for malignant germ cell tumors of the ovary. *Obstet Gynecol* 2003;101:251–7.
23. Chapman RM, Sutcliffe SB. Protection of ovarian function by oral contraceptives in women receiving chemotherapy for Hodgkin's disease. *Blood* 1981;58:849–51.
24. Whitehead E, Shalet SM, Blackledge G, Todd I, Crowther D, Beardwell CG. The effect of combination chemotherapy on ovarian function in women treated for Hodgkin's disease. *Cancer* 1983;52:988–93.
25. Glode LM, Robinson J, Gould SF. Protection from cyclophosphamide-induced testicular damage with an analogue of gonadotropin-releasing hormone. *Lancet* 1981;1:1132–4.
26. Ataya KM, McKanna JA, Weintraub AM, Clark MR, LeMaire WJ. A luteinizing hormone-releasing hormone agonist for the prevention of chemotherapy-induced ovarian follicular loss in rats. *Cancer Res* 1985;45:3651–6.
27. Bokser L, Szende B, Schally AV. Protective effects of D-Trp6-luteinizing hormone-releasing hormone microcapsules against cyclophosphamide-induced gonadotoxicity in female rats. *Br J Cancer* 1990;61:861–5.
28. Ataya K, Rao LV, Lawrence E, Kimmel R. Luteinizing hormone-releasing hormone agonist inhibits cyclophosphamide-induced ovarian follicular depletion in rhesus monkeys. *Biol Reprod* 1995;52:365–72.
29. Waxman JH, Ahmed R, Smith D, Wrigley PF, Gregory W, Shalet S, et al. Failure to preserve fertility in patients with Hodgkin's disease. *Cancer Chemother Pharmacol* 1987;19:159–62.
30. Krause W, Pfluger KH. Treatment with the gonadotropin-releasing hormone agonist buserelin to protect spermatogenesis against cytotoxic treatment in young men. *Andrologia* 1989;21:265–70.
31. Blumenfeld Z, Avivi I, Linn S, Epelbaum R, Ben-Shahar M, Haim N. Prevention of irreversible chemotherapy-induced ovarian damage in young women with lymphoma by a gonadotrophin-releasing hormone agonist in parallel to chemotherapy. *Hum Reprod* 1996;11:1620–6.
32. Blumenfeld Z, Haim N. Prevention of gonadal damage during cytotoxic therapy. *Ann Med* 1997;29:199–206.
33. Blumenfeld Z, Dann E, Avivi I, Epelbaum R, Rowe JM. Fertility after treatment for Hodgkin's disease. *Ann Oncol* 2002;13:138–47.
34. Montz FJ, Wolff AJ, Gambone JC. Gonadal protection and fecundity rates in cyclophosphamide-treated rats. *Cancer Res* 1991;51:2124–6.
35. Familiari G, Caggiati A, Nottola SA, Ermini M, Di Benedetto MR, Motta PM. Ultrastructure of human ovarian primordial follicles after combination chemotherapy for Hodgkin's disease. *Hum Reprod* 1993;8:2080–7.
36. Tilly JL. Apoptosis and ovarian function. *Rev Reprod* 1996;1:162–72.
37. Tilly JL. The molecular basis of ovarian cell death during germ cell attrition, follicular atresia, and luteolysis. *Front Biosci* 1996;1:d1–d11.
38. Morita Y, Tilly JL. Oocyte apoptosis: like sand through an hourglass. *Dev Biol* 1999;213:1–17.
39. Tilly JL. Molecular and genetic basis of normal and toxicant-induced apoptosis in female germ cells. *Toxicol Lett* 1998;102:3:497–501.
40. Morita Y, Perez GI, Paris F, Miranda SR, Ehleiter D, Haimovitz-Friedman A, et al. Oocyte apoptosis is suppressed by disruption of the acid sphingomyelinase gene or by sphingosine-1-phosphate therapy. *Nat Med* 2000;6:1109–14.
41. Meirow D, Schenker JG, Rosler A. Ovarian hyperstimulation syndrome with low oestradiol in non-classical 17 alpha-hydroxylase, 17,20-lyase deficiency: what is the role of oestrogens? *Hum Reprod* 1996;11:2119–21.
42. Damewood MD, Grochow LB. Prospects for fertility after chemotherapy or radiation for neoplastic disease. *Fertil Steril* 1986;45:443–59.
43. Clough KB, Goffinet F, Labib A, Renolleau C, Campana F, de la Rochefordiere A, et al. Laparoscopic unilateral ovarian transposition prior to irradiation: prospective study of 20 cases. *Cancer* 1996;77:2638–45.
44. Husseinzadeh N, Nahhas WA, Velkley DE, Whitney CW, Mortel R. The preservation of ovarian function in young women undergoing pelvic radiation therapy. *Gynecol Oncol* 1984;18:373–9.
45. Gaetini A, De Simone M, Urgesi A, Levis A, Resegotti A, Ragona R, et al. Lateral high abdominal ovariopexy: an original surgical technique for protection of the ovaries during curative radiotherapy for Hodgkin's disease. *J Surg Oncol* 1988;39:22–8.
46. Williams RS, Littell RD, Mendenhall NP. Laparoscopic oophoropexy and ovarian function in the treatment of Hodgkin disease. *Cancer* 1999;86:2138–42.
47. Anderson B, LaPolla J, Turner D, Chapman G, Buller R. Ovarian transposition in cervical cancer. *Gynecol Oncol* 1993;49:206–14.
48. Howell SJ, Shalet SM. Fertility preservation and management of gonadal failure associated with lymphoma therapy. *Curr Oncol Rep* 2002;4:443–52.
49. Howell S, Shalet S. Gonadal damage from chemotherapy and radiotherapy. *Endocrinol Metab Clin N Am* 1998;27:927–43.
50. Covens AL, van der Putten HW, Fyles AW, Leung PM, O'Brien PF, Murphy KJ, et al. Laparoscopic ovarian transposition. *Eur J Gynaecol Oncol* 1996;17:177–82.
51. Hadar H, Loven D, Herskovitz P, Bairey O, Yagoda A, Levavi H. An evaluation of lateral and medial transposition of the ovaries out of radiation fields. *Cancer* 1994;74:774–9.
52. Howard FM. Laparoscopic lateral ovarian transposition before radiation treatment of Hodgkin disease. *J Am Assoc Gynecol Laparosc* 1997;4:601–4.
53. Belinson JL, Doherty M, McDay JB. A new technique for ovarian transposition. *Surg Gynecol Obstet* 1984;159:157–60.
54. van Beurden M, Schuster-Uitterhoeve AL, Lammes FB. Feasibility of transposition of the ovaries in the surgical and radiotherapeutic treatment of cervical cancer. *Eur J Surg Oncol* 1990;16:141–6.
55. Bidzinski M, Lemieszczuk B, Zielinski J. Evaluation of the hormonal function and features of the ultrasound picture of transposed ovary in cervical cancer patients after surgery and pelvic irradiation. *Eur J Gynaecol Oncol* 1993;14:77–80.
56. Chambers SK, Chambers JT, Kier R, Peschel RE. Sequelae of lateral ovarian transposition in irradiated cervical cancer patients. *Int J Radiat Oncol Biol Phys* 1991;20:1305–8.
57. Feeny DD, Moore DH, Look KY, Stehman FB, Sutton GP. The fate of the ovaries after radical hysterectomy and ovarian transposition. *Gynecol Oncol* 1995;56:3–7.
58. Siddle N, Sarrel P, Whitehead M. The effect of hysterectomy on the age at ovarian failure: identification of a subgroup of women with premature loss of ovarian function and literature review. *Fertil Steril* 1987;47:94–100.
59. Morice P, Juncker L, Rey A, El-Hassan J, Haie-Meder C, Castaigne D. Ovarian transposition for patients with cervical carcinoma treated by radiosurgical combination. *Fertil Steril* 2000;74:743–8.
60. Chambers SK, Chambers JT, Holm C, Peschel RE, Schwartz PE. Sequelae of lateral ovarian transposition in unirradiated cervical cancer patients. *Gynecol Oncol* 1990;39:155–9.
61. Bashist B, Friedman WN, Killackey MA. Surgical transposition of the ovary: radiologic appearance. *Radiology* 1989;173:857–60.
62. Kier R, Chambers SK. Surgical transposition of the ovaries: imaging findings in 14 patients. *AJR Am J Roentgenol* 1989;153:1003–6.
63. Jarrell MA, Brumsted JR. Successful treatment of a persistent cyst, developing after ovarian transposition, with leuprolide acetate. *Obstet Gynecol* 1990;76:927–8.
64. Treissman MJ, Miller D, McComb PF. Laparoscopic lateral ovarian transposition. *Fertil Steril* 1996;65:1229–31.
65. Yarali H, Demiroglu A, Bukulmez O, Coskun F, Gurgan T. Laparoscopic high lateral transposition of both ovaries before pelvic irradiation. *J Am Assoc Gynecol Laparosc* 2000;7:237–9.
66. Morice P, Castaigne D, Haie-Meder C, Pautier P, El Hassan J, Du-villard P, et al. Laparoscopic ovarian transposition for pelvic malignancies: indications and functional outcomes. *Fertil Steril* 1998;70:956–60.
67. Sutton GP, Bundy BN, Delgado G, Sevin BU, Creasman WT, Major FJ, et al. Ovarian metastases in stage IB carcinoma of the cervix: a Gynecologic Oncology Group study. *Am J Obstet Gynecol* 1992;66:50–3.
68. Webb GA. The role of ovarian conservation in the treatment of carcinoma of the cervix with radical surgery. *Am J Obstet Gynecol* 1975;122:476–84.
69. Ranney B, Abu-Ghazaleh S. The future function and fortune of ovarian tissue which is retained in vivo during hysterectomy. *Am J Obstet Gynecol* 1977;128:626–34.
70. Smith PG, Doll R. Late effects of x irradiation in patients treated for metropathia haemorrhagica. *Br J Radiol* 1976;49:224–32.
71. Bieler EU, Schnabel T, Knobel J. Persisting cyclic ovarian activity in cervical cancer after surgical transposition of the ovaries and pelvic irradiation. *Br J Radiol* 1976;49:875–9.
72. Larson JE, Whitney CW, Zaino R, Kaminski P, Podczaski E, Mortel R. Endometrial response to endogenous hormones after pelvic irradiation for genital malignancies. *Gynecol Oncol* 1990;36:106–9.
73. Barnhill D, Heller P, Dames J, Hoskins W, Gallup D, Park R. Persistence of endometrial activity after radiation therapy for cervical carcinoma. *Obstet Gynecol* 1985;66:805–8.

74. Critchley HO, Jones RL, Lea RG, Drudy TA, Kelly RW, Williams AR, et al. Role of inflammatory mediators in human endometrium during progesterone withdrawal and early pregnancy. *J Clin Endocrinol Metab* 1999;84:240–8.
75. Morice P, Thiam-Ba R, Castaigne D, Haie-Meder C, Gerbaulet A, Pautier P, et al. Fertility results after ovarian transposition for pelvic malignancies treated by external irradiation or brachytherapy. *Hum Reprod* 1998;13:660–3.
76. Tulandi T, Al-Took S. Laparoscopic ovarian suspension before irradiation. *Fertil Steril* 1998;70:381–3.
77. Bisharah M, Tulandi T. Laparoscopic preservation of ovarian function: an underused procedure. *Am J Obstet Gynecol* 2003;188:367–70.
78. Swerdlow AJ, Jacobs PA, Marks A, Maher EJ, Young T, Barber JC, et al. Fertility, reproductive outcomes, and health of offspring, of patients treated for Hodgkin's disease: an investigation including chromosome examinations. *Br J Cancer* 1996;74:291–6.
79. Fenig E, Mishaeli M, Kalish Y, Lishner M. Pregnancy and radiation. *Cancer Treat Rev* 2001;27:1–7.
80. Giacalone PL, Laffargue F, Benos P, Dechaud H, Hedon B. Successful in vitro fertilization-surrogate pregnancy in a patient with ovarian transposition who had undergone chemotherapy and pelvic irradiation. *Fertil Steril* 2001;76:388–9.
81. Fujiwara K, Mohri H, Yoshida T, Yamauchi H, Kohno I. Subcutaneous transposition of the ovary following hysterectomy. *Int J Gynaecol Obstet* 1997;58:223–8.
82. Anselmo AP, Cavalieri E, Aragona C, Sbracia M, Funaro D, Maurizi Enrico R. Successful pregnancies following an egg donation program in women with previously treated Hodgkin's disease. *Haematologica* 2001;86:624–8.
83. Ataya K, Pydyn E, Ramahi-Ataya A, Orton CG. Is radiation-induced ovarian failure in rhesus monkeys preventable by luteinizing hormone-releasing hormone agonists? Preliminary observations. *J Clin Endocrinol Metab* 1995;80:790–5.
84. Buekers TE, Anderson B, Sorosky JI, Buller RE. Ovarian function after surgical treatment for cervical cancer. *Gynecol Oncol* 2001;80:85–8.
85. Al-Hasani S, Diedrich K, van der Ven H, Reinecke A, Hartje M, Krebs D. Cryopreservation of human oocytes. *Hum Reprod* 1987;2:695–700.
86. Chen C. Pregnancies after human oocyte cryopreservation. *Ann NY Acad Sci* 1988;541:541–9.
87. Gook DA, Osborn SM, Johnston WI. Cryopreservation of mouse and human oocytes using 1,2-propanediol and the configuration of the meiotic spindle. *Hum Reprod* 1993;8:1101–9.
88. Gook DA, Osborn SM, Bourne H, Johnston WI. Fertilization of human oocytes following cryopreservation: normal karyotypes and absence of stray chromosomes. *Hum Reprod* 1994;9:684–91.
89. Tucker M, Wright G, Morton P, Shanguo L, Massey J, Kort H. Preliminary experience with human oocyte cryopreservation using 1,2-propanediol and sucrose. *Hum Reprod* 1996;11:1513–5.
90. Porcu E, Dal Prato L, Seracchioli R, Petracchi S, Fabbri R, Flamigni C. Births after transcervical gamete intrafallopian transfer with a falloposcopic delivery system. *Fertil Steril* 1997;67:1175–7.
91. Young E, Kenny A, Puigdomenech E, Van Thillo G, Tiveron M, Piazza A. Triplet pregnancy after intracytoplasmic sperm injection of cryopreserved oocytes: case report. *Fertil Steril* 1998;70:360–1.
92. Tucker MJ, Wright G, Morton PC, Massey JB. Birth after cryopreservation of immature oocytes with subsequent in vitro maturation. *Fertil Steril* 1998;70:578–9.
93. Szein JM, McGregor TE, Bedigian HJ, Mobraaten LE. Transgenic mouse strain rescue by frozen ovaries. *Lab Anim Sci* 1999;49:99–100.
94. Oktay K. Ovarian tissue cryopreservation and transplantation: preliminary findings and implications for cancer patients. *Hum Reprod Update* 2001;7:526–34.
95. Oktay K. Evidence for limiting ovarian tissue harvesting for the purpose of transplantation to women younger than 40 years of age. *J Clin Endocrinol Metab* 2002;87:1907–8.
96. Oktay K, Buyuk E. The potential of ovarian tissue transplant to preserve fertility. *Expert Opin Biol Ther* 2002;2:361–70.
97. Magistrini M, Szollosi D. Effects of cold and of isopropyl-N-phenyl-carbamate on the second meiotic spindle of mouse oocytes. *Eur J Cell Biol* 1980;22:699–707.
98. Stachecki JJ, Cohen J, Willadsen S. Detrimental effects of sodium during mouse oocyte cryopreservation. *Biol Reprod* 1998;59:395–400.
99. Albertini DF. Regulation of meiotic maturation in the mammalian oocyte: interplay between exogenous cues and the microtubule cytoskeleton. *Bioessays* 1992;14:97–103.
100. Oda K, Gibbons WE, Leibo SP. Osmotic shock of fertilized mouse ova. *J Reprod Fertil* 1992;95:737–47.
101. Hotamisligil S, Toner M, Powers RD. Changes in membrane integrity, cytoskeletal structure, and developmental potential of murine oocytes after vitrification in ethylene glycol. *Biol Reprod* 1996;55:161–8.
102. Fahy GM, Lilley TH, Linsdell H, Douglas MS, Meryman HT. Cryoprotectant toxicity and cryoprotectant toxicity reduction: in search of molecular mechanisms. *Cryobiology* 1990;27:247–68.
103. Chen C. Pregnancy after human oocyte cryopreservation. *Lancet* 1986;1:884–6.
104. Todorow SJ, Siebzehnrubl ER, Spitzer M, Koch R, Wildt L, Lang N. Comparative results on survival of human and animal eggs using different cryoprotectants and freeze-thawing regimens. II. Human. *Hum Reprod* 1989;4:812–6.
105. Porcu E. Freezing of oocytes. *Curr Opin Obstet Gynecol* 1999;11:297–300.
106. Fabbri R, Porcu E, Marsella T, Rocchetta G, Venturoli S, Flamigni C. Human oocyte cryopreservation: new perspectives regarding oocyte survival. *Hum Reprod* 2001;16:411–6.
107. Kuleshova LL, MacFarlane DR, Trounson AO, Shaw JM. Sugars exert a major influence on the vitrification properties of ethylene glycol-based solutions and have low toxicity to embryos and oocytes. *Cryobiology* 1999;38:119–30.
108. Kuleshova L, Gianaroli L, Magli C, Ferraretti A, Trounson A. Birth following vitrification of a small number of human oocytes: case report. *Hum Reprod* 1999;14:3077–9.
109. Carroll J, Wood MJ, Whittingham DG. Normal fertilization and development of frozen-thawed mouse oocytes: protective action of certain macromolecules. *Biol Reprod* 1993;48:606–12.
110. Oktay K, Nugent D, Newton H, Salha O, Chatterjee P, Gosden RG. Isolation and characterization of primordial follicles from fresh and cryopreserved human ovarian tissue. *Fertil Steril* 1997;67:481–6.
111. Oktay K, Karlikaya GG, Aydin BA. Ovarian cryopreservation and transplantation: basic aspects. *Mol Cell Endocrinol* 2000;169:105–8.
112. Cha KY, Koo JJ, Ko JJ, Choi DH, Han SY, Yoon TK. Pregnancy after in vitro fertilization of human follicular oocytes collected from non-stimulated cycles, their culture in vitro and their transfer in a donor oocyte program. *Fertil Steril* 1991;55:109–13.
113. Gook DA, Schiewe MC, Osborn SM, Asch RH, Jansen RP, Johnston WI. Intracytoplasmic sperm injection and embryo development of human oocytes cryopreserved using 1,2-propanediol. *Hum Reprod* 1995;10:2637–41.
114. Trounson A, Wood C, Kausche A. In vitro maturation and the fertilization and developmental competence of oocytes recovered from untreated polycystic ovarian patients. *Fertil Steril* 1994;62:353–62.
115. Toth TL, Lanzendorf SE, Sandow BA, Veeck LL, Hassen WA, Hansen K, et al. Cryopreservation of human prophase I oocytes collected from unstimulated follicles. *Fertil Steril* 1994;61:1077–82.
116. Bouquet M, Selva J, Auroux M. Cryopreservation of mouse oocytes: mutagenic effects in the embryo? *Biol Reprod* 1993;49:764–9.
117. Moller CC, Wassarman PM. Characterization of a proteinase that cleaves zona pellucida glycoprotein ZP2 following activation of mouse eggs. *Dev Biol* 1989;132:103–12.
118. Assisted reproductive technology in the United States: 1998 results generated from the American Society for Reproductive Medicine/Society for Assisted Reproductive Technology Registry. *Fertil Steril* 2002;77:18–31.
119. Meniru GI, Craft I. In vitro fertilization and embryo cryopreservation prior to hysterectomy for cervical cancer. *Int J Gynaecol Obstet* 1997;56:69–70.
120. Pelinck MJ, Hoek A, Simons AH, Heineman MJ. Efficacy of natural cycle IVF: a review of the literature. *Hum Reprod Update* 2002;8:129–39.
121. Oktay K, Buyuk E, Davis O, Yermakova I, Veeck L, Rosenwaks Z. Fertility preservation in breast cancer patients: IVF and embryo cryopreservation after ovarian stimulation with tamoxifen. *Hum Reprod* 2003;18:90–5.
122. Paynter SJ, Cooper A, Fuller BJ, Shaw RW. Cryopreservation of bovine ovarian tissue: structural normality of follicles after thawing and culture in vitro. *Cryobiology* 1999;38:301–9.
123. Mazur P. The role of intracellular freezing in the death of cells cooled at supraoptimal rates. *Cryobiology* 1977;14:251–72.
124. Gosden RG, Baird DT, Wade JC, Webb R. Restoration of fertility to oophorectomized sheep by ovarian autografts stored at –196 degrees C. *Hum Reprod* 1994;9:597–603.
125. Baird DT, Webb R, Campbell BK, Harkness LM, Gosden RG. Long-term ovarian function in sheep after ovariectomy and transplantation of autografts stored at –196 C. *Endocrinology* 1999;140:462–71.
126. Newton H, Aubard Y, Rutherford A, Sharma V, Gosden R. Low temperature storage and grafting of human ovarian tissue. *Hum Reprod* 1996;11:1487–91.
127. Candy CJ, Wood MJ, Whittingham DG. Effect of cryoprotectants on the survival of follicles in frozen mouse ovaries. *J Reprod Fertil* 1997;110:11–9.
128. Newton H, Fisher J, Arnold JR, Pegg DE, Faddy MJ, Gosden RG. Permeation of human ovarian tissue with cryoprotective agents in preparation for cryopreservation. *Hum Reprod* 1998;13:376–80.

129. Wang X, Chen H, Yin H, Kim SS, Lin Tan S, Gosden RG. Fertility after intact ovary transplantation. *Nature* 2002;415:385.
130. Bedaiwy MA, Jeremias E, Gurunluoglu R, Hussein MR, Siemianow M, Biscotti C, et al. Restoration of ovarian function after autotransplantation of intact frozen-thawed sheep ovaries with microvascular anastomosis. *Fertil Steril* 2003;79:594–602.
131. Felicio LS, Nelson JF, Gosden RG, Finch CE. Restoration of ovulatory cycles by young ovarian grafts in aging mice: potentiation by long-term ovariectomy decreases with age. *Proc Natl Acad Sci USA* 1983;80:6076–80.
132. Jeremias E, Bedaiwy MA, Nelson D, Biscotti CV, Falcone T. Assessment of tissue injury in cryopreserved ovarian tissue. *Fertil Steril* 2003;79:651–3.
133. Jeremias E, Bedaiwy MA, Gurunluoglu R, Biscotti CV, Siemionow M, Falcone T. Heterotopic autotransplantation of the ovary with microvascular anastomosis: a novel surgical technique. *Fertil Steril* 2002;77:1278–82.
134. Oktay K, Newton H, Mullan J, Gosden RG. Development of human primordial follicles to antral stages in SCID/hpg mice stimulated with follicle stimulating hormone. *Hum Reprod* 1998;13:1133–8.
135. Oktay K, Newton H, Gosden RG. Transplantation of cryopreserved human ovarian tissue results in follicle growth initiation in SCID mice. *Fertil Steril* 2000;73:599–603.
136. Weissman A, Gotlieb L, Colgan T, Jurisicova A, Greenblatt EM, Casper RF. Preliminary experience with subcutaneous human ovarian cortex transplantation in the NOD-SCID mouse. *Biol Reprod* 1999;60:1462–7.
137. Oktay K, Karlikaya G. Ovarian function after transplantation of frozen, banked autologous ovarian tissue. *N Engl J Med* 2000;342:1919.
138. Radford JA, Lieberman BA, Brison DR, Smith AR, Critchlow JD, Russell SA, et al. Orthotopic reimplantation of cryopreserved ovarian cortical strips after high-dose chemotherapy for Hodgkin's lymphoma. *Lancet* 2001;357:1172–5.
139. Oktay K, Economos K, Kan M, Rucinski J, Veeck L, Rosenwaks Z. Endocrine function and oocyte retrieval after autologous transplantation of ovarian cortical strips to the forearm. *JAMA* 2001;286:1490–3.
140. Callejo J, Salvador C, Miralles A, Vilaseca S, Laila JM, Balasch J. Long-term ovarian function evaluation after autografting by implantation with fresh and frozen-thawed human ovarian tissue. *J Clin Endocrinol Metab* 2001;86:4489–94.