

ANTIFERTILITY AND ULTRASTRUCTURAL EFFECTS OF OPTICAL ISOMERS OF GOSSYPOL ADMINISTERED INTRATESTICULARLY IN RATS

A. Agarwal

Andrology Laboratory, Division of Urology, Brigham and Women's Hospital and Harvard Medical School, 75 Francis Street, Boston, MA 02115

This study reports on the effects of optical isomers of gossypol administered intratesticularly on testicular ultrastructure and fertility in rats. Gossypol isomers were administered to adult male rats by daily intratesticular injections for up to two days at a dose of 1200 µg/testis. The results of this study have demonstrated that the intratesticular injection of racemic and (–) gossypol at a dose of 1200 µg for 1 or 2 days mimic the effect of gossypol on rat testis after oral administration of 20 to 30 mg dose for 5-7 weeks,² (–)-gossypol was found to be 81% effective in inducing mitochondrial sheath damage in the late spermatids of stage VI, VII and VIII tubules compared to 67% for racemic and 7% for (+)-gossypol,³ the intratesticular injection of (±) and (–)-gossypol (1200 µg/testis, daily for 1 or 2 days) induces complete infertility three weeks after the last injection.

Introduction

The effect of gossypol on male fertility and on the morphology and biochemistry of the testes, epididymides and epididymal sperm has been the subject of considerable attention in recent years. Gossypol is known to be effective as male contraceptive in several mammalian species, including man, but problems related to reversibility and hypokalemia have arisen in some patients taking this drug (Qian and Wang, 1984²⁰). Although efforts to synthesize chemical analogs of gossypol which lack adverse effects have resulted in several compounds which are active as spermicides *in vitro*, none of these compounds have been successful as an antifertility agent *in vivo* (Wang, Lou and Tang, 1979;²⁷ Manmade, Herlihy, Quick, Duffley, Burgos and Hoffer, 1983;¹³ Meltzer, Bickford and Lambert, 1985;¹⁵ Hoffer, Agarwal, Meltzer, Herlihy, Naqvi, Lindberg and Matlin, 1987;⁷ Hoffer, Agarwal, Meltzer, Naqvi and Matlin, 1988;⁸ Sonenberg, Huang, Ren, Su, Watanabe, Haspel, Corin and Hoffer, 1988²³). The discrepancy between the activity of test compounds *in vivo* and *in vitro* has been especially perplexing in the case of diethylgossypol (Meltzer et al., 1985;¹⁵ Hoffer et al., 1987;⁷ 1988⁸) a compound which differs from gossypol by the absence of only one methyl group in the isopropyl moiety. *In vitro*, diethylgossypol is a potent spermicide against hamster sperm but *in vivo* it is entirely devoid

of contraceptive activity in the same species (Hoffer et al., 1987;⁷ 1988⁸); similar discrepancies have been observed with other chemical analogs of gossypol also.

It is not clear why compounds so similar in structure should differ so radically in physiological activity. A possible explanation is that the bioavailability of the test compounds may be limited, resulting in their failure to reach the germ cells in sufficient concentrations to interfere with their functions. An alternate possibility is that the test compounds undergo structural changes in the body which render them inactive at the target sites. Questions concerning the bioavailability of orally-administered experimental contraceptives have prompted us to utilize intratesticular injections of water-soluble forms of gossypol (gossypol-PVP) and related compounds as a means of exploring their antifertility potential. This approach combines the advantages of an *in vivo* and *in vitro* system so that morphological and contraceptive effects of known amounts of test compounds can be evaluated in the whole animal with the speed and low requirements for test compounds normally expected from *in vitro* assay systems. In addition, this test system minimizes the possibility of testicular effects due to interference by metabolic products of gossypol produced elsewhere in the body and enhances the bioavailability of gossypol in the testis due to its local administration and water solubility. The purpose of the present paper is to report for the first time the mor-

Key words: Gossypol, Antifertility, Testis, Intratesticular, Ultrastructural

phological and antifertility effects of intratesticular injections of 1200 ugms of (\pm), (+) and (—)-gossypol-PVP in adult rats.

Materials and methods

Preparation of Co-Precipitates of Gossypol and of Other Analogs with Polyvinyl-pyrrolidone (PVP)

Gossypol and its analogs were bound to PVP (Eastern Kodak Company, Mol. Wt. = 40,000) in order to obtain water-soluble compounds according to the procedure of Waller, Zaneveld and Fong (1980²⁶) gossypol-PVP co-precipitate was prepared by dissolving gossypol in a minimum volume of ether and diluting with methanol to a concentration of 0.01 g/ml, resulting in a final solution containing no more than 1% ether. PVP was dissolved in a minimum volume of methanol and mixed with the gossypol solution in the ratio of 4:1. Solvents were removed *in vacuo* at 40°C utilizing a rotary evaporator initially set at half speed when the volume was minimal in order to insure the formation of a co-precipitate having a fluffy consistency.

Intratesticular Injections

For each stereoisomer and time interval tested, male rats were injected in each testis with 1200 ug of (\pm), (+) or (—)-gossypol-PVP or PVP saline alone. Intratesticular injections were performed by making a small incision in the scrotum, exposing the testis and carefully injecting 200 ul of the test solution with a 30 gauge needle fitted to a 1 ml tuberculin syringe. The incision was then closed by a 4.0 silk suture. Care was taken to avoid damage to any major testicular blood vessels and to avoid testicular infection by using a fresh needle for each injection. Appropriate control animals using PVP-saline alone received intratesticular injections according to the same schedule.

Light and Electron Microscopic Studies

Sexually mature male rats (CD strain, Charles River Laboratories) weighing 300-325 g were employed for ultrastructural studies. Animals were divided into four treatment groups according to the regimen and stereoisomers used. Control rats in Group I (n = 5) received daily intratesticular injections of PVP-saline (1200 ug/testis) for 1 and 2 days. Group II rats were injected daily with (\pm) gossypol-PVP (1200 ug/testis) for 1 and 2 days (n = 10). Rats in Group III were treated with intratesticular injections of (+)-gossypol-PVP (1200 ug/testis/day) for 1 and 2 days (n = 5); rats in Group IV received intratesticular injections of (—)-gossypol-PVP (1200 ug/day) for 1 and 2 days also (n = 7).

At the end of the experiment, the rats were anaesthetized and their testes exposed by scrotal incision. The spermatic

cord was gently dissected free and ligated twice, approximately 0.5 cm apart; the cord in between the ligatures was severed. The testis was transferred to a 10 ml beaker filled with saline and the testicular artery was cannulated with a 25 gauge needle attached to a 25 cm piece of polyethylene tubing (Clay Adams PE 60). This tubing was connected by a 3-way valve to a standard 140 cm high perfusion system. The testis was flushed briefly with 0.9% saline then perfused with 5% glutaraldehyde in 0.1 M collidine buffer (pH 7.4). Immediately after the saline entered the testicular artery, the spermatic cord was severed proximal to the ligature to provide a route for the effluent. After the testis blanched (about 10 seconds), saline was replaced with fixative and the perfusion continued for 25 minutes. The testis remained immersed in fixative for an additional 45-60 minutes thereafter. Tissues were then cut into 1 mm thick blocks, rinsed briefly in buffer and postosmicated in 1.33% OsO₄, and buffered with 0.1 M collidine buffer for 2-3 hours. The tissues were dehydrated in a series of increasing concentrations of cold acetone and embedded in Araldite. Thin sections showing pale gold interference colors were cut with a diamond knife on a Sorvall MT-6000 microtome and stained with uranyl acetate (1:1 solution of saturated uranyl acetate and ethanol) followed by lead citrate (Venable & Coggeshall, 1965²⁴). Sections were examined under a Phillips 200 or Jeolco 100 S electron microscope. For light microscopy, sections were cut from the same blocks at 0.5 to 1.0 μ thickness and stained with toluidine blue.

Late spermatids in stages 6 to 9 were observed under electron microscope to detect gossypol defects in the mitochondrial sheath of step 18 & 19 spermatids. The number of tubules showing gossypol damage in late spermatid stages were counted and percentage of affected tubules was calculated as follows:

$$\frac{\text{Number of tubules showing gossypol defects}}{\text{Total number of tubules scored}} \times 100$$

Chi-square test was used to calculate the level of significance P value less than 0.01 was considered to be significant.

Mating Studies

Mating studies were conducted to evaluate the fertility of rats intratesticularly injected with 1200 ug of (\pm), (+) or (—)-gossypol-PVP or PVP alone in 200 ul sterile saline per testis for 2 days. Sexually mature males (n = 40) weighing between 300-325 gm and female CD rats (n = 240) weighing between 225-275 gm from Charles River Laboratories were divided into 4 groups. Group I: control animals received 1200 ug PVP/testis, daily for 2 days (n = 10); Group II: 1200 ug (\pm)-gossypol-PVP/testis, daily for 2 days (n = 12); Group III: 1200 ug (+)-gossypol-PVP/testis/day for 2 days (n = 12); Group IV: 1200 ug (—)-gossypol-PVP/testis/day for 2 days (n = 11)

At the end of each injection regimen, the males were isolated and kept in wire mesh cages for 2 weeks. Two weeks after the last injection the males were individually housed with 2 sexually mature females for 6 days. Males were separated from females on the 7th day and were housed with fresh set of females on the 8th day. Mating studies were conducted 2, 3 and 4 weeks after the last intratesticular injection. Females were sacrificed 7 days after the end of cohabitation period and pregnancy was confirmed by counting the number of embryos in both horns of uterus. The males were considered to be fertile if they impregnate any of the 2 females. The percent fertility was calculated as follows:

$$\% \text{ fertility} = \frac{\text{Number of fertile male}}{\text{Total number of males used for mating}} \times 100$$

Results

Morphological Studies with Racemic Gossypol-PVP

The morphological effects of intratesticular injections of 1200 ug/testis of racemic gossypol-PVP and PVP-saline alone were examined after 1 and 2 days of treatment and compared with those in rats made infertile with orally-administered gossypol. Earlier observations on the histological and ultrastructural changes seen in testes of rats treated orally with gossypol (Hoffer, 1983⁵) served as a baseline for the present study and can be briefly summarized as follows. Specific electron microscopic defects in the mitochondrial sheath of step 18 and 19 spermatid were observed by the 5th week of oral administration of gossypol. At the same oral dose, but at time intervals of 7-11 weeks, 10-20% of the seminiferous tubules exhibit varying amounts of intraepithelial vacuolization due primarily to the formation of Sertoli cell vacuoles. This vacuolization, a well known non-specific response of Sertoli cells to various forms of injury (Fawcett, 1975³) occurs after the decline in fertility and the appearance of the step 18 and 19 spermatid mitochondrial defects, suggesting that the Sertoli cell changes are not related to gossypol's antifertility effect.

In the present study, light microscopic observation on the control group of intratesticularly injected rats exhibited no differences in testicular histology between PVP-saline injected (Figs. 1 and 2) and uninjected animals after 1 and 2 days. Sertoli cells and germinal cells in different stages of development were present in all seminiferous tubules. Interstitial elements including Leydig cells, blood and lymphatic vessels and connective tissue cells were also entirely normal in their appearance throughout the testis. The ultrastructural features of the seminiferous epithelium, including the mitochondrial sheath of step 18 and 19 spermatids (Fig. 3) and interstitial elements were also normal in all respects in 1 and 2 day PVP-saline injected control animals.




Fig. 1 - Intratesticular injections of PVP-saline administered to control rats at a dose of 1200 ug/testis/day for 2 days. The light micrographs of control rat testis injected for 2 days show seminiferous tubules with normal histological appearance. No differences between PVP-saline injected or uninjected (not shown here) testes are observed after 2 days. $\times 850$.



Fig. 2 - Intratesticular injections of PVP-saline administered to control rats at a dose of 1200 ug/testis/day for 2 days. The light micrographs of control rat testis injected for 2 days show seminiferous tubules with normal histological appearance. No differences between PVP-saline injected or uninjected (not shown here) testes are observed after 2 days. $\times 850$.

One day after intratesticular injection of racemic gossypol-PVP, the seminiferous epithelium looked normal at the light microscope level except that some intraepithelial vacuolization and premature sloughing in step 19 spermatids was observed in few affected tubules. The Sertoli cells appeared unaffected. No effect on the Leydig cells, blood and lymphatic vessels in the interstitium was observed. However, at the ultrastructural level, 25% of the seminiferous tubules exhibited mitochondrial sheath defects in step 18 and 19 spermatids after 1 day intratesticular injections of racemic gossypol-




Fig. 3 - Electron micrograph of a stage VII seminiferous tubule from a testis intratesticularly injected with PVP-saline (1200 ug/testis/day for 2 days). Notice that the mitochondrial sheaths of the step 19 spermatids appear completely normal. The alignment of the mitochondria around the axonemal complex is regular, the cristae are neither swollen nor collapsed and there are no major discontinuities or ruptured mitochondria along the length of the mid-piece. $\times 11000$.

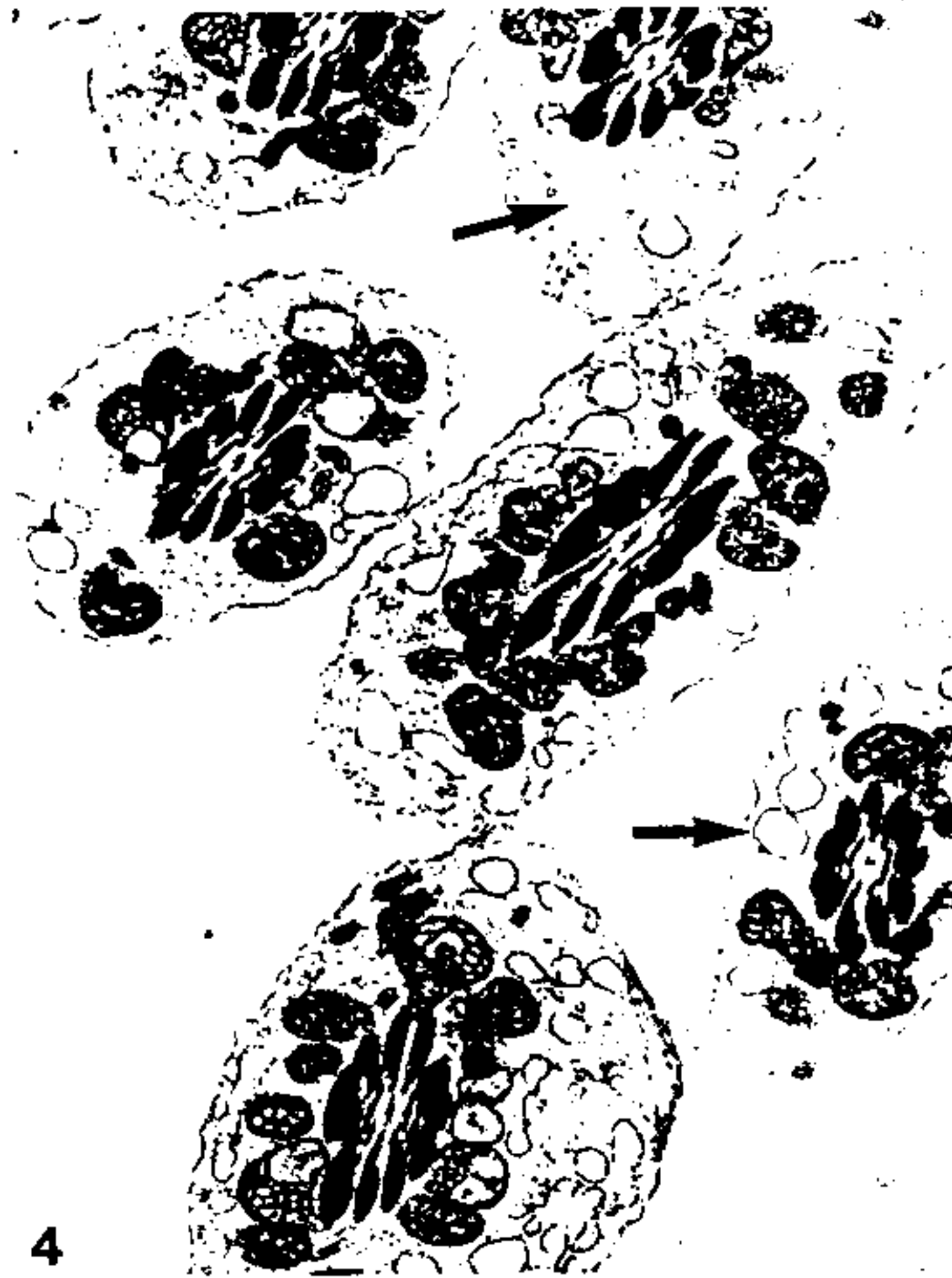


Fig. 4 - In rats intratesticularly injected with racemic gossypol-PVP (1200 ug/testis/day) for 2 days, slight defects in the mitochondrial sheath in step 18 and 19 spermatids can occasionally be observed. As shown in this electron micrograph, some of the affected mitochondria lack cristae or exhibit small vacuoles in place of cristae (c.f. Fig. 3) $\times 25000$.

PVP. Some of the affected mitochondria lacked cristae or exhibited small vacuoles in place of cristae (Fig. 4). Occasional discontinuities in the mitochondrial sheath were also a characteristic feature in this treatment group. These mitochondrial defects were similar to those induced after daily oral administration of 10, 20 and 30 mg/kg of gossypol acetic acid for 5 weeks (Hoffer, 1983⁵).

After 2 days of intratesticular injections of (\pm)-gossypol-PVP, the light microscope changes in the testis were more pronounced. As animals treated for 1 day, premature sloughing of step 18 and 19 spermatids was observed (Figs 5 and 6). In addition, some non-specific effects of gossypol treatment such as intraepithelial vacuolization, vacuolization of round spermatid nuclei and multinucleate giant cell formation was also seen. At the ultrastructural level, 67% of the seminiferous tubules exhibited pathognomonic defects in the

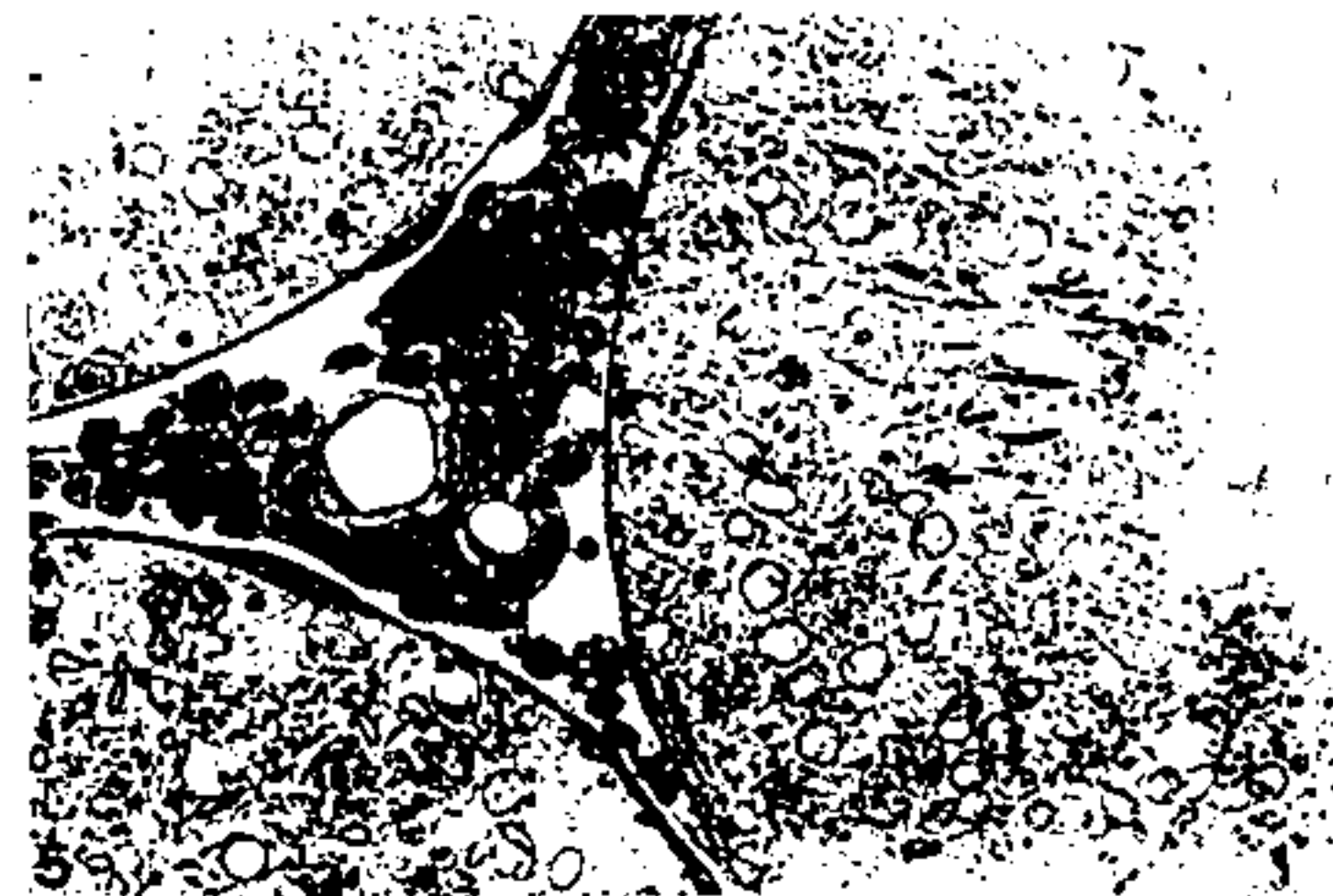


Fig. 5 - After 2 days of intratesticular injection with racemic gossypol-PVP (1200 ug/testis/day), more pronounced changes in the rat testis are observed, including premature sloughing of elongated spermatids, intraepithelial vacuolization and vacuolization of round spermatid nuclei (c.f. Fig. 1 and 2) $\times 850$.

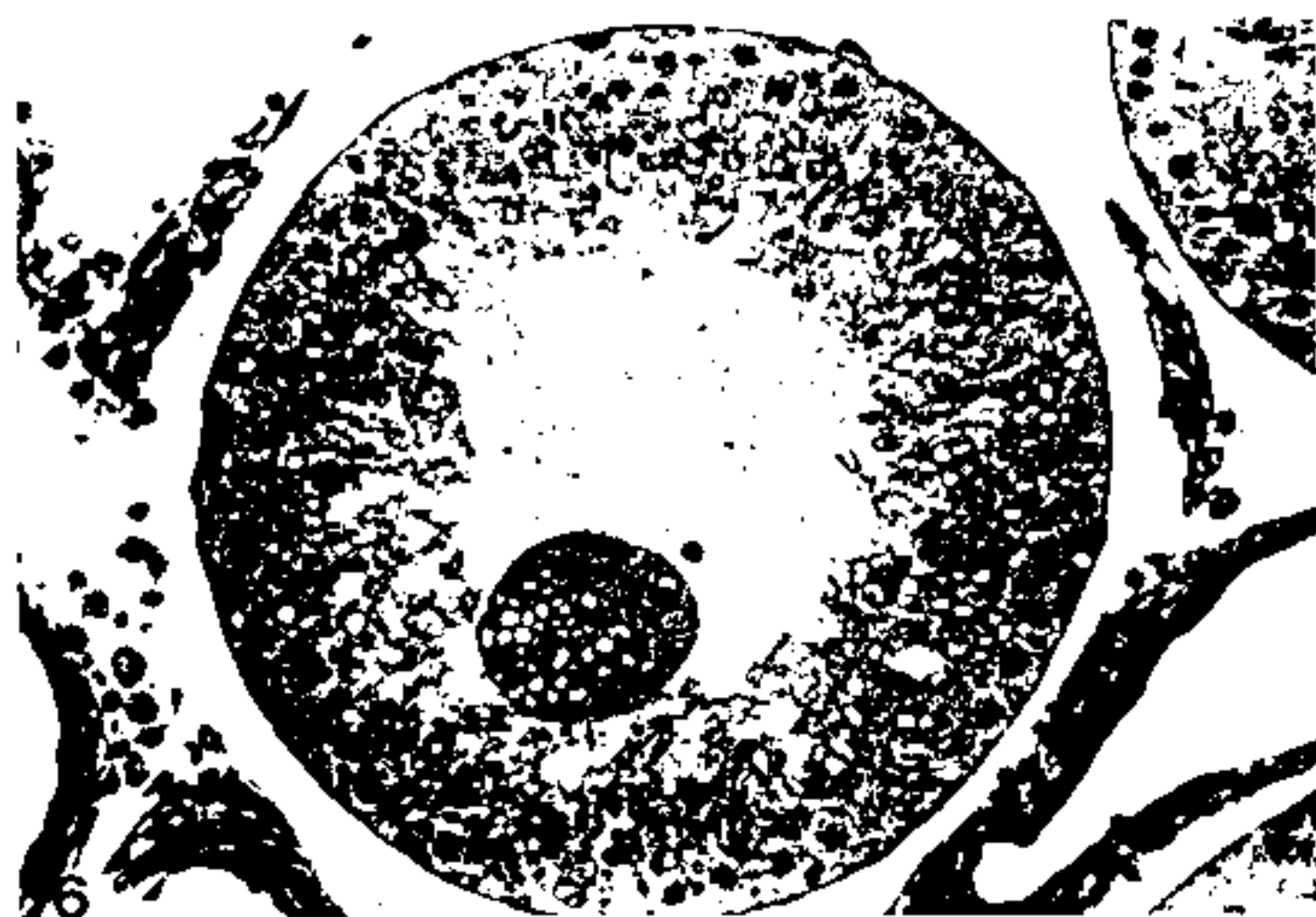

Fig. 6 - After 2 days of intratesticular injection with racemic gossypol-PVP (1200 ug/testis/day), more pronounced changes in the rat testis are observed, including premature sloughing of elongating spermatids, intraepithelial vacuolization and vacuolization of round spermatid nuclei (c.f. Fig. 1 and 2) $\times 425$.

midpiece of step 18 and 19 spermatids after 2 days of intratesticular injections. Midpiece defects especially discontinuities and degeneration in the mitochondrial sheath seen in this treatment group were similar to earlier observations (Hoffer, 1983⁵). No ultrastructural difference in Leydig cell structure could be observed between control or 2 day gossypol-PVP injected rats.

Morphological Studies with (-)-Gossypol-PVP

In order to determine whether intratesticular injection of the potent (-)-gossypol-PVP can produce morphological effects similar to or more severe than that of comparable doses of intratesticularly injected racemic gossypol, the effects of daily injections of 1200 ug of (-)-gossypol-PVP for 1 and 2 days were examined. At the ultrastructural level, the differences between the effects of the (-) and (\pm)-isomers on mitochondrial sheaths of late spermatids were not significantly different (Table I).

Table I - Percentage of Affected Seminiferous Tubules^a in Rats Receiving Intratesticular Injections of Saline-PVP, (+)-Gossypol-PVP, (-)-Gossypol-PVP or (\pm)-Gossypol-PVP (1200 ug/testis/day) For 2 Days

Group	Percent Affected Tubules	Chi-Square Value	P Value
I: PVP-Saline ^b	0%	7.2	<0.01
II: (+)-Gossypol-PVP ^b	7%		
II: (+)-Gossypol-PVP	7%		
III: (\pm)-Gossypol-PVP ^b	67%	76.6	<0.01
II: (+)-Gossypol-PVP	7%		
IV: (-)-Gossypol-PVP ^b	81%	112.5	<0.01
III: (+)-Gossypol-PVP	67%		
IV: (-)-Gossypol-PVP	81%		NS

^a Tubules showing mitochondrial defects in late spermatids.
^b Number of testes scored in each group was five.

However, significant differences ($P < 0.01$) between the effects of (-)-gossypol-PVP and PVP-saline injected rats (1200 ug/testis, daily for 1 and 2 days) on mitochondrial sheaths of late spermatids were observed. Histological changes in the testis at the light microscope level in (-) and (\pm) intratesticularly injected animals were also similar in nature and included sloughing of late spermatids in lumen, intraepithelial vacuolization and vacuolization of round spermatid nuclei (Figs. 7, 8 and 9).

Morphological Studies with (+)-Gossypol-PVP

To ascertain whether intratesticular injection of (+)-gossypol-PVP can produce the same morphological effects as (-) and (\pm) at comparable doses, the effects of daily injections of 1200 ug of (+)-gossypol-PVP for 1 and 2 days were examined. No significant differences between the light microscope effects of intratesticularly-injected (+)-gossypol-PVP and the other two isomeric forms were

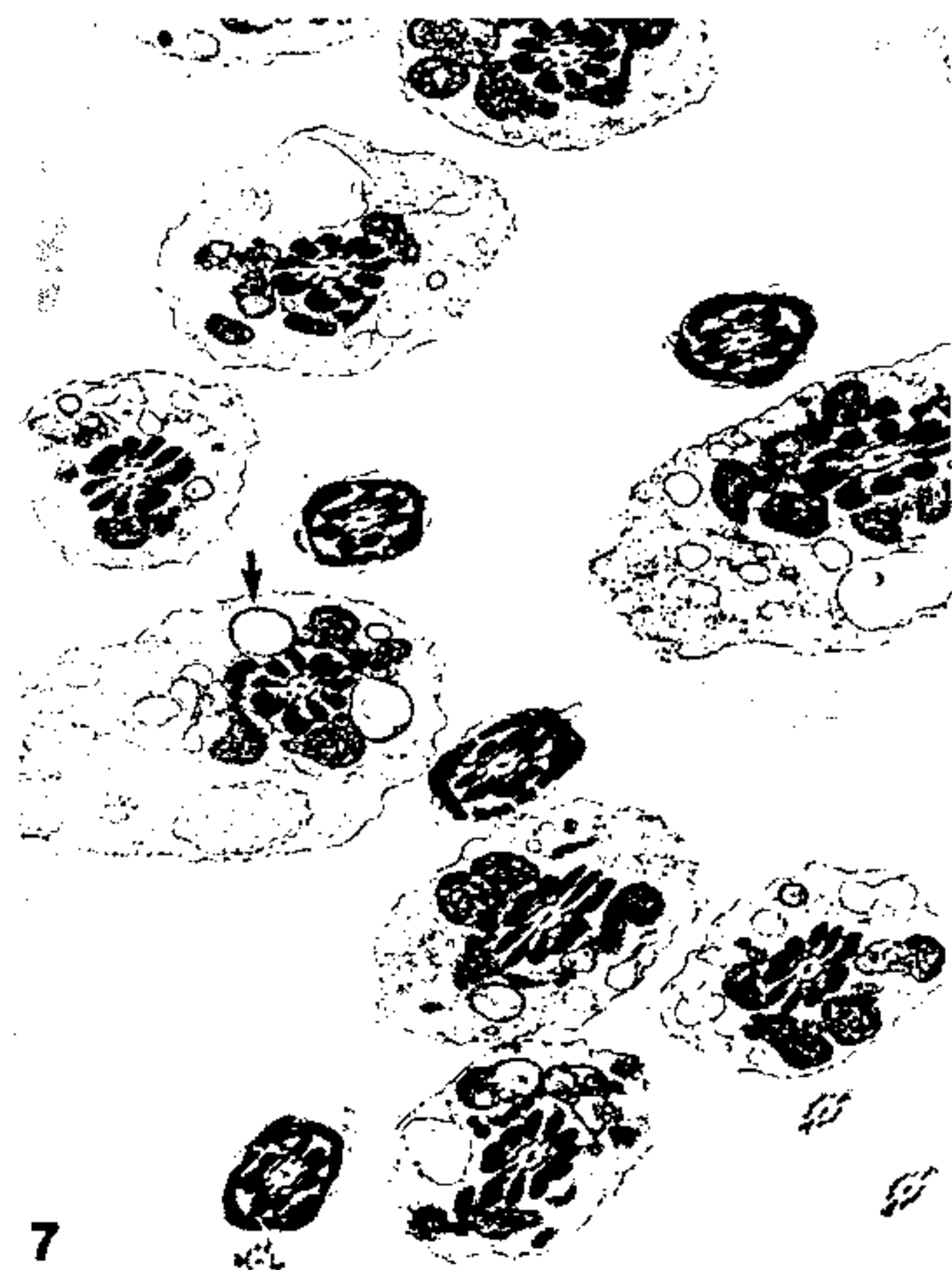

Fig. 7 - Electron micrograph of step 19 spermatids after intratesticular injection with (-)-gossypol-PVP (1200 ug/testis/day) for 2 days showing severe mitochondrial sheath defects in late spermatids. Notice the severely vacuolated and disoriented mitochondria which have fallen away from the axonemal complex; several midpiece profiles can be recognized in which the outer dense fibers are almost completely denuded of mitochondria. $\times 11000$.

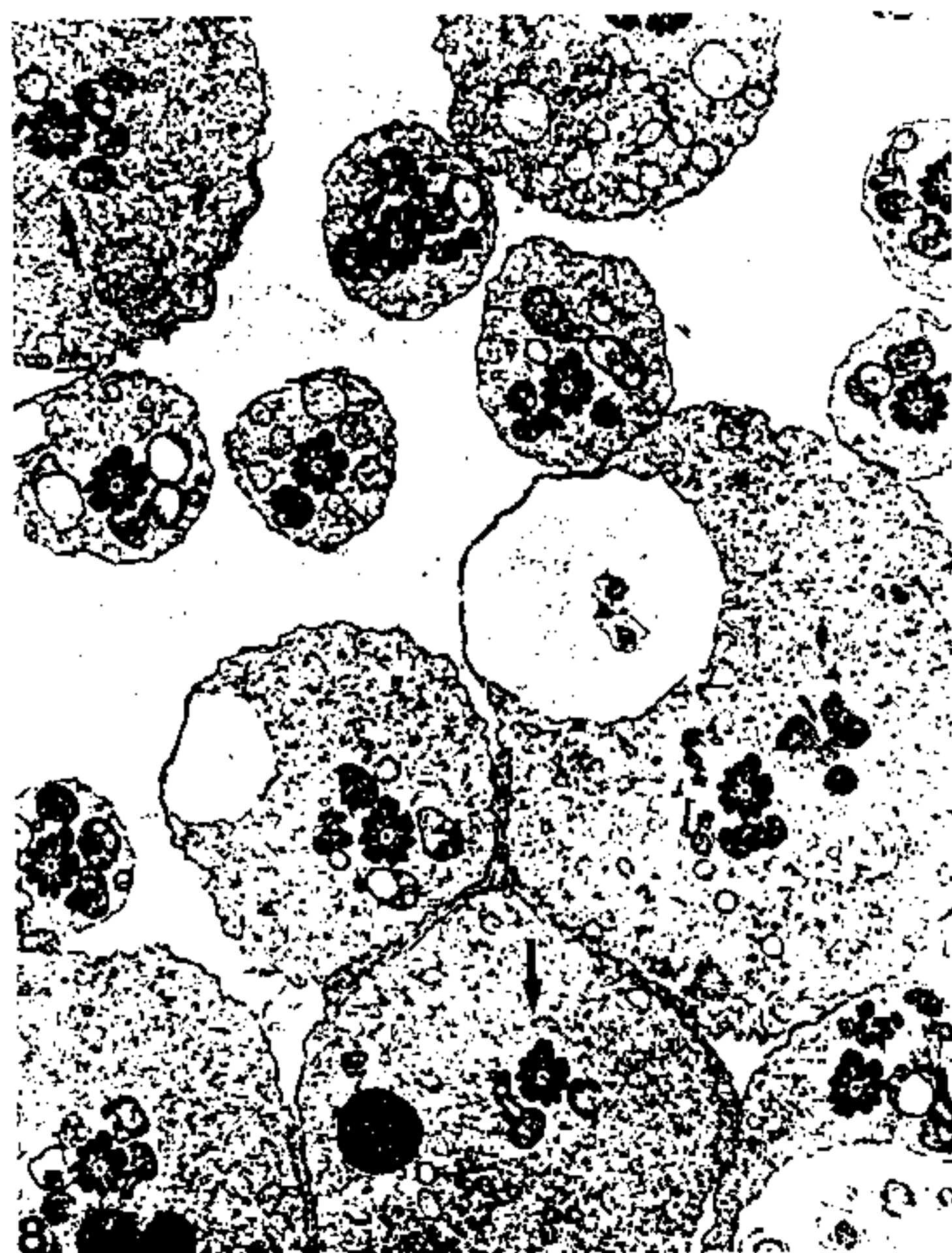


Fig. 8 Electron micrograph of step 19 spermatids after intratesticular injection with (—)-gossypol-PVP (1200 ug/testis/day) for 2 days showing severe mitochondrial sheath defects in late spermatids. Notice the severely vacuolated and disoriented mitochondria which have fallen away from the axonemal complex; several midpiece profiles can be recognized in which the outer dense fibers are almost completely denuded of mitochondria. $\times 9000$.

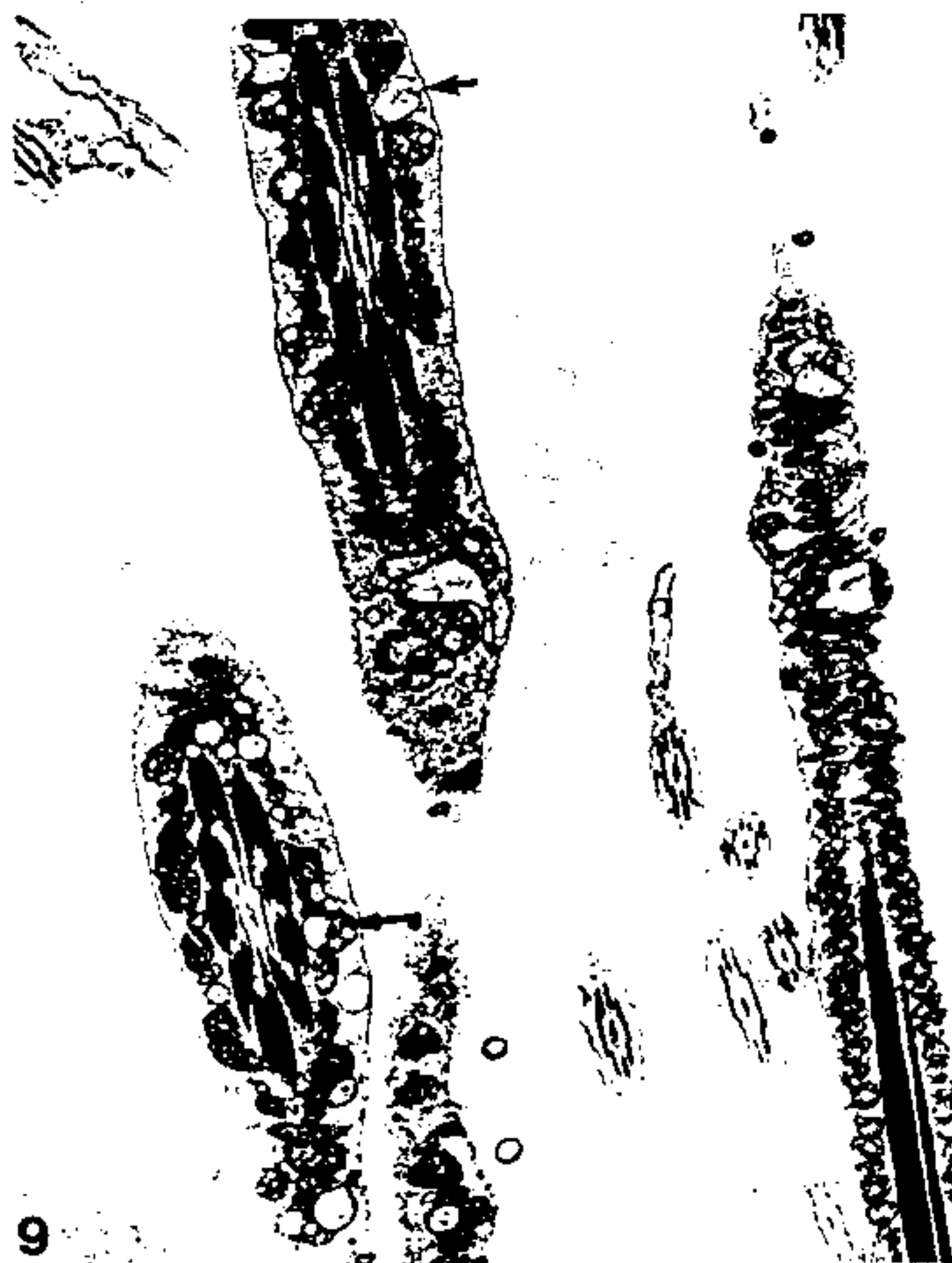

Fig. 9 - Severe mitochondrial defects in the mitochondrial sheath of step 17 spermatids are shown in this electron micrograph from another rat intratesticularly injected with (—)-gossypol-PVP (1200 ug/testis/day) for 2 days). Marked vacuolization and degeneration of the cristae can easily be recognized in the mitochondria. Changes as severe as these are almost never seen in testes injected for comparable lengths of time with the PVP-coprecipitate of the racemic isomer. $\times 13000$.

detected. However, at the ultrastructural level, a significantly lower rate of degenerating and/or deleted mitochondria in midpieces of step 18 and 19 spermatids of (+)-gossypol-PVP injected rats was observed (Table I); other morphological characteristics of the seminiferous epithelium were similar to those in the (\pm) and (—)-isomer treatment groups. Significant differences ($P < 0.01$) between the effects of (+)-gossypol-PVP and control PVP-saline injected (1200 ug/testis, daily for 2 days) rats on mitochondrial sheath of late spermatids was observed. No changes between these two groups after 1 day of injection with the same dose was found.

Fertility Studies

The results of the fertility studies are shown in Table II. It was found that all males injected with either racemic gossypol-PVP or (—)-gossypol-PVP (1200 ug/testis, daily for 2 days)

Table II - Fertility in Rats Receiving Intratesticular Injections of Saline-PVP, (+)-Gossypol-PVP, (—)-Gossypol-PVP or (\pm)-Gossypol-PVP (1200 ug/day) for Two Days

Group	2 Weeks After Last Injection	3 Weeks After Last Injection	4 Weeks After Last Injection
I: (n = 10) ^a Saline-PVP	100%	90%	90%
II: (n = 12) (+)-Gossypol-PVP	100%	100%	100%
III: (n = 12) (—)-Gossypol-PVP	42%	0%	0%
IV: (n = 11) ^b (\pm)-Gossypol-PVP	73%	0%	0%

^a Group I originally had 13 males, testes in 3 of the males became infected; hence only the remaining 10 (uninfected) males were scored.

^b Group IV originally had 14 males, but testes in 3 males became infected; hence only the remaining 11 (uninfected) males were scored.

were infertile by the third week after cessation of treatment, whereas all the males injected with (+)-gossypol-PVP and majority of the PVP-saline injected controls were fertile. At the end of the mating study, the males were sacrificed in order to examine the reproductive tract. In some cases, males were found to have developed testicular infections four weeks after the last injection (see Table II for details) in the form of adhesions, swelling etc; caudal sperm from these animals were immotile. The data from females mated with males found to have testicular infections 4 weeks after last injection was not included in this study, as it was not possible to ascertain whether females mated with these males became infertile because of drug action or due to testicular infection. Utmost care was taken to avoid testicular infections by using fresh needles for each testis injected and by using sterilized instruments.

Discussion

Numerous investigators have employed intratesticular injections to study a variety of agents or phenomena (Russell, Malone and MacCrudy, 1981;²¹ Russell;²² Wiebe and Barr, 1984²⁸) however, there are no reports on the effects of microquantities of gossypol isomers (+), (—) and (±) on the testicular ultrastructure or fertility after intratesticular injections. The morphological, ultrastructural and antifertility effects of (+), (—) and (±)-gossypol isomers at similar dose and length of treatment is reported here for the first time. The present study has clearly demonstrated that intratesticular injections of (±)-gossypol-PVP at a dose of 1200 µgm for 1 or 2 days mimic the effect of gossypol on rat testis after oral administration of 20 to 30 mg dose for 5-7 weeks (Hoffer, 1983⁵). After 1 day of intratesticular injections of (±)-isomer, slight defects in the mitochondrial sheath (absence of cristae, discontinuities in mitochondrial sheath, etc.) in step 18 and 19 spermatids were observed. These mitochondrial defects were similar to those induced after daily oral administration of 10, 20 and 30 mg/kg gossypol acetic acid for 5 weeks (Hoffer, 1983⁵). No significant differences in the intensity of light microscopic changes, viz: intraepithelial vacuolization, premature exfoliation of germ cells, vacuolization of round spermatid nuclei, giant cell formation and presence of degenerating cells, was observed in the testis after intratesticular injection of either (+), (—) or (±) gossypol-PVP complexes at a dose of 1200 µgm, daily for 1 or 2 days. At the ultrastructural level, however, a significantly lower rate of degenerating and/or deleted mitochondria in mid-pieces of step 18 and 19 spermatids was observed in (+)-gossypol-PVP injected testis as compared to either (±) or (—) isomers. Similarly, a striking difference between the effects of (—) and (±) isomers on the testicular ultrastructure was observed in the present study. (—)-gossypol-PVP was found to be almost 81% effective in inducing mitochon-

drial sheath damage (deletions and degenerations of cristae) in the late spermatids of stage VI, VII & VIII tubules compared to (±) gossypol-PVP which causes milder effects (disorganization, discontinuities of mitochondrial sheath, etc.) in fewer tubules (67%). The finding of our study that (—)-gossypol-PVP is more effective in inducing pathognomonic defects in mitochondrial sheath of late spermatids than (±) gossypol is in agreement with reports that antifertility activity of (—) isomer in hamster is twice as much as the racemic mixture (Matlin, Zhou, Bialy, Blye, Naqui and Lindberg, 1985¹⁴). This is not surprising since (+)-gossypol has been reported to be inactive (Waller, Bunyaphatsara, Martin, Vournazos, Ahmed, Soejarto, Cordell, Fong, Russell and Malone, 1983²⁵). The presence of (+)-gossypol in the racemic mixture may provide some protection against the effect of (—)-gossypol by competing for the same site of action.

The presence of complete infertility in rats intratesticularly injected with racemic and (—)-gossypol (1200 µgm/testis, daily for 1 or 2 days) three weeks after the last injection is in agreement with earlier reports (Hoffer, 1982⁴). The three week interval between initiation of gossypol treatment and the appearance of defective spermatozoa in the caput epididymidis may indicate that gossypol has a direct effect on germ cells (step 18 and 19 spermatids) in the testis and that this length of time is required before the damaged cell reach the epididymal duct.

Clinical trials in China, Japan and Brazil, as well as numerous animal studies, leave little doubt that gossypol is an antifertility agent (National Coordinating Group, 1978;¹⁷ Hoshiai, Vehara, Mari, Nagaike, Tsuike and Suzuki, 1982;⁹ Prasad & Diczfalussy, 1982;¹⁹ Coutinho, 1984;² Hoffer, 1985⁶). However, very little is known about the mechanism of action of gossypol, a number of reports have described its effects on spermatogenesis and sperm metabolism. Administration of gossypol to rats in high doses leads to mitochondrial and flagellar damage in testicular and epididymal spermatozoa (Hoffer, 1982;⁴ 1983;⁵ Oko and Hrudka, 1982¹⁸) and to a decrease of sperm ATP content with a concomitant loss of motility (Ke & Tso, 1982¹⁶). Biochemical evidence indicates that gossypol interacts either with specific enzymes in mitochondria, including succinate dehydrogenase, cytochrome oxidase and microsomal oxidase (Lyman, 1959¹², Myers & Thornberry, 1966¹⁶) or with proteins (Ko, Lin, Lin, Chang, Mar, Yu and Din, 1979;¹¹ Lyman, 1959¹²). Being a polyphenolic compound it also possesses an oxidative phosphorylation uncoupling effect (Abou-Donia & Dieckert, 1974¹). The present study emphasizes the importance of using the intratesticular injection which offers several potential benefits over other routes of administration (viz: intraperitoneal, intravenous, oral, etc.) used to expose the testis to various agents. Intratesticular injection can be used to study direct effects of agents of unknown toxicity to the testis. Alternatively, agents whose effects are very specific and well doc-

umented can be injected to observe the consequences of disruption of specific pathways/organelles. The most important advantage of this route of drug administration is the reduction in the amount of drug injected, significant reduction in the length of drug treatment and lastly presence of no artificial effects due to multiple entry of injection needle into the testis.

Acknowledgements

This work was supported by a grant from the Rockefeller Foundation (RF88044).

References

- 1) Abou-Donia M.B., Dieckert J.W.: Uncoupling of respiratory chain and oxidative phosphorylation. *Life Sciences* 14: 1955, 1974.
- 2) Coutinho Y.: Kinetics of spermatogenesis in mammals: seminiferous epithelium cycle and spermatogonial renewal. *Physiological Review* 52: 198, 1972.
- 3) Fawcett D.W.: Ultrastructure and function of the Sertoli cell. In *Handbook of Physiology*, section on endocrinology, Vol. 5. Edited by E.B. Astwood and R.O. Greep, Bethesda. American Physiological Society, Publishers, 1975, p. 259.
- 4) Hoffer A.P.: Ultrastructural studies of spermatozoa and the epithelial lining of the epididymis and vas deferens in rats treated with gossypol. *Arch. Androl.* 8: 233, 1982.
- 5) Hoffer A.P.: Effect of gossypol on the seminiferous epithelium in the rats: A light and electron microscope study. *Biol. Reprod.* 28: 1007, 1983.
- 6) Hoffer A.P.: Ultrastructural, biochemical and endocrine studies on the effects of gossypol and its isomeric derivatives on the male reproductive tract. In *Gossypol: A potential Contraceptive for Men*. Edited by S.J. Segal, New York, Plenum Press, Publishers 1985, p. 143.
- 7) Hoffer A.P., Agarwal A., Meltzer P., Herlihy P., Naqvi R.H., Lindberg M.C., Matlin S.A.: Ultrastructural, fertility and spermicidal studies with isomers and derivatives of gossypol in male hamsters.
- 8) Hoffer A.P., Agarwal A., Meltzer P., Naqvi R., Matlin S.A.: Antifertility, spermicidal and ultrastructural effects of gossypol and derivatives administered orally and by intratesticular injections. *Contraception* 37: 301, 1988.
- 9) Hoshiai H., Vehara S., Mori R., Nagaike F., Tsuiki A., Suzuki M.: Gossypol as oral contraceptive for male: trial case report. *J. Exp. Med.* 138: 275, 1982.
- 10) Ke Y.B., Tso W.W.: Variations of gossypol susceptibility in rat spermatozoa during spermatogenesis. *Int. J. Fert.* 27: 42, 1982.
- 11) Ko Y.B., Lin X.K., Lin X.Y., Chang Y.H., Mar Y.W., Yu S.E., Din Y.: Studies on the antifertility effect of gossypol. III. The determination of the quantities of gossypol in blood and related internal organs after administration of the drug in rats. *Acta Biol. Exp. Sin.* 12: 59, 1979.
- 12) Lyman C.M.: Reactions of protein with gossypol. *Arch. Biochem. Biophys.* 84: 486, 1959.
- 13) Manmade A., Herlihy P., Quick J., Duffley R.P., Burgos M., Hoffer A.P.: Gossypol: Synthesis and *in vitro* spermicidal activity of isomeric hemi gossypol derivatives. *Experimentia* 39: 1276, 1983.
- 14) Matlin S.A., Zhou R., Bialy G., Blye R.P., Naqvi R.H., Lindberg M.C.: (—)-Gossypol: an active male antifertility agent. *Contraception* 31: 141, 1985.
- 15) Meltzer P.C., Bickford P.H., Lamberg G.J.: A regioselective route to gossypol analogues: The synthesis of gossypol and 5,5'-didesisopropyl-5'5 diethylgossypol. *J. Org. Chem.* 50: 3121, 1985.
- 16) Myers B.D., Thornberry G.O.: Effect of gossypol on some oxidative-respiratory enzymes. *Plant. Physiol.* 41: 787, 1966.
- 17) National Coordinating Group on Male Antifertility Agents: Gossypol - a new antifertility agent for males. *Chinese Medical Journal* 4: 417, 1978.
- 18) Oko R., Hrudka F.: Segmental aplasia of the mitochondrial sheath and sequelae induced by gossypol in rat spermatozoa. *Biol. Reprod.* 26: 183, 1982.
- 19) Prasad M.R.N., Diczfalusy E.: Gossypol. *Int. J. Androl. Supplement* 5: 53, 1980.
- 20) Qian S.Z., Wang Z.G.: A potential antifertility agent for males. *Ann. Rev. Pharmacol. Toxicol.* 24: 329, 1984.
- 21) Russell L.D., Malone J.P., MacCrudy D.: Effects of the microtubule disrupting agents, colchicine and vinblastine, on seminiferous tubule structure in rat. *Tissue and Cell* 13: 349, 1981.
- 22) Russell L.D.: Normal testicular structure and methods of evaluation under experimental and disruptive conditions. In *Reproductive and Developmental Toxicity of Metals*, Edited by T.W. Clarkson, F.F. Nordberg and P.R. Sager, New York, Plenum Publishing Corp, Publishers 1983, p. 227.
- 23) Sonnenberg M., Huang J.T., Ren Y.F., Su T.L., Watanabe K.A., Haspel H.C., Corin R.E., Hoffer A.P.: Antifertility and other actions of gossypol analogues. *Contraception* 37: 247, 1988.
- 24) Venable J.H., Coggeshall R.: A simplified lead citrate stain for use in electron microscopy. *J. Cell. Biol.* 25: 407, 1965.
- 25) Waller D.P., Bunyaphatsara N., Martin A., Vournazos C.J., Ahmed M.D., Soejarto D.D., Cordell G.A., Fong H.H.S., Russell L.D., Malone J.P.: Effect of (+)-gossypol on fertility in male hamsters. *J. Androl.* 4: 276, 1983.
- 26) Waller D.P., Zanefeld L.J.D., Fong H.H.S.: *In vitro* spermicidal activity of gossypol. *Contraception* 22: 183, 1980.
- 27) Wang Y., Luo X., Tang X.: Studies on the antifertility actions of cotton seed meal and gossypol. *Acta Pharmaceut. Sin.* 14: 662, 1979.
- 28) Wiebe J.P., Barr K.J.: Suppression of spermatogenesis without inhibition of steroidogenesis by a 1, 2, 3-trihydroxypropane solution. *Life Sciences* 34: 1747, 1984.

Address requests for reprints to:

A. Agarwal Ph.D.

Andrology Laboratory, MRB 414

Brigham and Women's Hospital

75 Francis Street - Boston, MA 02115 - USA